The New England
Journal of Medicine

Copyright, 1944, by the Massachusetts Medical Society

Volume 230 FEBRUARY 3, 1944 Number 5

PERITONEOSCOPY IN LIVER DISEASE*

EDWARD B. BENEDICT, M.D.†

BOSTON

IN a series of 435 peritoneoscopies[1-3] performed during the last few years at the Massachusetts General Hospital, the question of liver disease arose in 331, or 70 per cent, of the cases examined. The instrument designed by Ruddock[4, 5] was used in all cases. It is therefore evident that one of the chief uses of the peritoneoscope is in the diagnosis of liver disease.

When one considers that many of these patients are seriously ill and that in most of them an exploratory laparotomy is out of the question, the value of a precise diagnosis by peritoneoscopy is apparent. In comparing peritoneoscopy with exploration it should be pointed out that the former procedure requires only a 1-cm. incision under local anesthesia, an overnight stay in the hospital and minimum risk or discomfort to the patient. In 435 peritoneoscopies there have been 3 deaths (0.73 per cent) probably attributable to the procedure: one, a death from heart failure in a patient with multiple lung abscesses, coronary disease and possible echinococcal cyst of the liver; the second, a death due in part to hemorrhage eight days after peritoneoscopy with liver biopsy for extensive metastatic carcinoma; and the third, a death three weeks after perforation of the large bowel in a severely ill patient proved by peritoneoscopy to have advanced tuberculous peritonitis. These patients were all extremely sick, and it was probably unwise to subject the first one to peritoneoscopy, but many very sick patients can safely undergo the procedure if carefully watched by a competent assistant.

The preparation of the patient with liver disease for peritoneoscopy is of considerable importance, for frequently there is jaundice and liver damage. If the prothrombin time is prolonged, vitamin K is administered to reduce the bleeding tendency. Morphine and its derivatives, as well as the barbiturates, are to be avoided. Chloral hydrate may be safely substituted. Otherwise the patient is prepared as for any laparotomy, including an abdominal shave and scrub, and emptying of the stomach and bladder. The usual site of puncture for inspection of the liver is in the midline just above the umbilicus. The technic of the procedure has been described in previous reports.[1-5]

In a general way the cases of liver disease may be divided into two groups — the malignant and the nonmalignant. The 260 cases of liver disease in this series were classified as shown in Table 1.

TABLE 1. *Classification of Cases of Liver Disease.*

MALIGNANT		NONMALIGNANT	
Metastatic carcinoma	170	Cirrhosis	73
Primary carcinoma	5	Cholangitis	2
Melanotic sarcoma	1	Banti's disease	2
Malignant lymphoma	1	Lymphangioma	2
		Polycystic liver	1
Total	177	Echinococcal cyst	1
		Sarcoid	1
		Enlarged liver	1
		Total	83

In the remaining 71 cases there was found to be an essentially normal liver. From the above tabulation it is evident that carcinoma and cirrhosis are by far the commonest diagnoses. So the question often to be decided by peritoneoscopy is the following: Is there any disease in the liver and, if so, is it cancer, cirrhosis or something unsuspected?

The cases referred for peritoneoscopy because of liver disease usually fall into one of the following groups:

Metastatic carcinoma. In this group there is a positive or presumptive clinical diagnosis of carcinoma of the breast, bronchus, esophagus, stomach, pancreas, colon, rectum, prostate or the like, and before planning medical, x-ray or surgical treatment it may be of great importance to know whether or not there is metastatic disease in the liver.

Hepatomegaly. Is one dealing with metastatic or primary carcinoma, cirrhosis, hepatitis, sarcoma, echinococcal cyst, polycystic liver or some other liver disease?

Ascites. Is this due to cirrhosis, carcinoma or tuberculous peritonitis?

Jaundice. Is the diagnosis toxic cirrhosis, biliary cirrhosis, malignant neoplasm, hepatitis or some other infectious process?

*From the Massachusetts General Hospital.

†Instructor in surgery, Harvard Medical School; associate visiting surgeon, Massachusetts General Hospital.

Doubtful clinical findings. What is the precise diagnosis?

Primary carcinoma of liver.

Metastatic Carcinoma

In this group the primary source is oftener in the stomach than in any of the other organs. Peritoneoscopy was performed in 95 cases of carcinoma of the stomach, 75 of which showed no metastases and 20 of which did show metastases. Thus, a laparotomy was avoided in 20 cases (21 per cent). During a five-year period (1937-1941), 263 patients with cancer of the stomach were explored surgically without peritoneoscopy and in 39, or 15 per cent, the cases were found to be inoperable because of liver metastases. If peritoneoscopy had been performed in these cases, thirty-nine laparotomies might have been avoided and over a year in hospital days saved.

CASE 1. J. K., (M.G.H. U-334286), a 56-year-old Russian porter, was first admitted to the hospital complaining of abdominal pain of 5 weeks' duration, associated with anorexia, nausea, vomiting and a weight loss of 15 pounds during the previous 6 weeks.

Physical examination showed slight resistance and tenderness in the epigastrium. There was no palpable mass and the liver was not felt. A large carcinoma of the stomach was reported by x-ray.

Peritoneoscopy revealed several yellow, umbilicated lesions in the liver, characteristic of metastatic carcinoma. Numerous, small nodules were seen on the anterior surface of the stomach consistent with carcinomatous invasion of the serosal surface. A biopsy was obtained from one of the lesions in the liver. The pathological report was metastatic carcinoma. Laparotomy was therefore not done.

Clinically this case was operable. The patient was only fifty-six years old and was well developed and nourished, and no abdominal mass was palpable. Except for the positive evidence of metastatic cancer in the liver at peritoneoscopy, he would probably have been subjected to a fruitless exploratory laparotomy.

If, on the other hand, no metastatic disease is demonstrable by peritoneoscopy, the patient should be explored surgically. Sometimes, as in the following case, when a patient appears clinically to be inoperable a favorable peritoneoscopy report encourages a successful resection.

CASE 2. M. J. (M.G.H. U-99960), a 77-year-old, unemployed Irishman, was admitted to the hospital complaining of indigestion and an abdominal lump. He had been perfectly well until 3 months before admission, when he gradually developed epigastric distress and soreness after meals. Four weeks previously he had noted a lump in the epigastrium.

Physical examination disclosed a midepigastric, apple-sized movable mass. X-ray examination showed extensive cancer of the distal half of the stomach.

Peritoneoscopy revealed a normal liver and no evidence of peritoneal metastases or of extension of the growth through the gastric wall. Operation was therefore undertaken, and although there were carcinomatous lymph nodes along the lesser curvature, a gastric resection was successfully carried out.

In addition to cancer of the liver metastatic from the stomach, peritoneoscopy has in many cases demonstrated metastatic disease in the liver when the primary source was in the breast, bronchus, esophagus, pancreas, colon, rectum or prostate or was of undetermined origin. In some of these cases, exploratory operation was thus avoided.

Hepatomegaly

CASE 3. G. S. R. (B.M. U-389474), a 35-year-old lumber salesman, entered the hospital because of enlargement of the abdomen of 1 week's duration. For 12 years there had been an excessive intake of alcohol, with anorexia for 6 months. There had been a recent 10-pound weight loss.

Physical examination showed jaundice, enlargement of the liver to below the umbilicus and ascites. The temperature varied from 98 to 102°F. A clinical diagnosis of alcoholic cirrhosis was made but, because of the large liver and the fever, malignancy was also considered.

Peritoneoscopy showed a granular, slightly nodular liver of mottled brown, red and yellow color. There was no evidence of malignancy. A biopsy resulted in a diagnosis of cirrhosis, alcoholic type.

In this case of hepatomegaly with jaundice, ascites and weight loss, peritoneoscopy confirmed the clinical diagnosis of alcoholic cirrhosis and excluded carcinoma.

CASE 4. F. H. S. (B.M. U-305683), a 71-year-old man, was referred to the hospital with a diagnosis of carcinoma of the stomach. He gave a history of anorexia and a 25-pound weight loss of 3 months' duration. There was also increasing fatigue and left-sided gas pain occurring 1 to 2 hours after meals.

Physical examination showed a small, elderly man with evidence of recent weight loss. The left lobe of the liver appeared to be enlarged. X-ray examination showed rigidity of the middle third of the lesser curvature of the stomach with narrowing of the antrum. The findings were those of carcinoma of the middle third of the stomach.

Peritoneoscopy was advised to determine whether or not metastases were present in the liver. Contrary to expectation, it showed a granular, almost hobnail liver, suggestive of cirrhosis. A small amount of ascitic fluid was also found and aspirated. A biopsy of the liver resulted in a diagnosis of toxic cirrhosis. Because of these findings no operation was performed. About 3 months later the patient died, and autopsy showed carcinoma of the stomach with metastases to the retroperitoneal and mesenteric lymph nodes and to the peritoneum, advanced portal cirrhosis of the liver, acute generalized fibrinous peritonitis, ascites and arteriosclerosis.

This case is presented to show how peritoneoscopy revealed an unsuspected cirrhosis of the liver in a patient known to have carcinoma of the stomach. Laparotomy was avoided.

CASE 5. I. M. P. (M.G.H U-309910), a 60-year-old Negress, entered the hospital because of weakness and discomfort in the epigastrium for 4 months.

Physical examination was essentially negative except for a smooth, firm mass in the epigastrium and the right upper quadrant of the abdomen, which was thought to be liver. Differential diagnoses by various members of the staff included metastatic carcinoma, cirrhosis, syphilis, melanotic sarcoma, lymphoma, hemachromatosis, amyloid disease and echinococcal cyst. Various laboratory and x-ray studies failed to give a positive diagnosis.

Peritoneoscopy showed the liver edge to be sharp but somewhat thick. The surface was granular and reddish brown. There was no evidence of malignancy. A biopsy resulted in a diagnosis of nonspecific hepatitis. One month later, when the patient was seen in the Out Patient Department, she was feeling well, her appetite was good, and the liver was still enlarged.

In this case of hepatomegaly, peritoneoscopy explained the enlarged liver by a positive diagnosis of hepatitis.

Certain other cases of hepatomegaly are of interest and may be included in this group. Briefly summarized, they are as follows:

CASE 6. M. G. T. (M.G.H. U–286198), a 71-year-old woman, was admitted with masses in both upper quadrants thought to be an enlarged spleen and liver. The clinical diagnosis was possible acute disseminated lupus or possible Gaucher's splenomegaly.

Peritoneoscopy showed masses in both upper quadrants due to extensive metastatic carcinoma involving both lobes of the liver. The biopsy report was metastatic adenocarcinoma.

CASE 7. E. E. (M.G.H. U–202726), a 52-year-old woman, was admitted complaining of anorexia and abdominal discomfort. A deep-lying, hard, nodular mass in the right upper quadrant and the epigastrium was clinically diagnosed as retroperitoneal sarcoma or an enlarged liver.

Peritoneoscopy demonstrated extensive carcinomatous implants in the liver. The biopsy report was metastatic adenocarcinoma.

CASE 8. O. L. (M.G.H. U–179499), a 60-year-old man with a history of extreme alcoholism, was admitted complaining of epigastric pain and tenderness. A hard, tender mass was found in the right upper quadrant. The clinical diagnosis was possible cirrhosis, or possible lymphoma.

Peritoneoscopy revealed extensive carcinoma of the liver. The biopsy report was metastatic adenocarcinoma, with the primary source not determined.

CASE 9. J. F. M. (M.G.H. U–360839), a 57-year-old woman, entered the hospital with a history of easy fatigue dyspnea, cough, nausea and vomiting. The liver was not palpable to several examiners, each of whom reported that he was unable to make a diagnosis. Another observer, however, thought the liver was enlarged, with some epigastric tenderness. X-ray examination confirmed a diagnosis of enlargement of the liver.

Peritoneoscopy revealed a liver filled with umbilicated, yellow nodules characteristic of carcinoma. The biopsy report was metastatic adenocarcinoma, Grade 3.

CASE 10. N. L., A 30-year-old, alcoholic man, entered the hospital because of an enormous liver that he himself had felt. The presumptive diagnosis was cirrhosis.

Peritoneoscopy, however, showed no evidence of cirrhosis, but demonstrated that the anterior surface of both lobes contained numerous slightly elevated, smooth, rounded, yellowish-gray lesions from 1 to 3 cm. in diameter, consistent with metastatic carcinoma, although not typically nodular or umbilicated. The biopsy report was lymphosarcoma.

In the last case, the clinical diagnosis of alcoholic cirrhosis was changed by peritoneoscopy, and the presumptive peritoneoscopic diagnosis of carcinoma was changed by biopsy to lymphosarcoma.

Ascites

CASE 11. L. L. (M.G.H. U–340612), a 55-year-old, Italian-born laborer, entered the hospital because of progressive enlargement of the abdomen of 2 months' duration, associated with anorexia and a dull pain in the left upper quadrant. All his life he had drunk two glassfuls of wine a day.

Physical examination revealed a greatly distended abdomen with slightly dilated superficial veins. A fluid wave was present. The liver was palpable about 8 cm. below the costal margin. The tip of the spleen was felt to descend to the iliac crest. There was also a hard, palpable, semicircular mass in the rectum 2 cm. above the prostate. The clinical diagnosis was cirrhosis of the liver, but carcinoma of the rectum with secondary implants in the liver was also considered.

At peritoneoscopy 7000 cc. of cloudy, yellow fluid was aspirated. The peritoneal surfaces throughout the abdomen were covered with gelatinous, tapioca-like, nodular, translucent material, characteristic of metastatic carcinoma. The liver edge appeared sharp and the surface did not appear cirrhotic. The latter was, however, partially covered with numerous translucent, metastatic lesions that did not appear to involve the parenchyma. The liver edge was at the costal margin. The palpable masses were neither the liver nor the spleen but were large, carcinomatous masses, probably involving the omentum. A biopsy at the peritoneum resulted in a diagnosis of metastatic colloid carcinoma.

In this patient with marked ascites and upper abdominal masses thought to be liver or spleen, the clinical diagnosis was alcoholic cirrhosis, but peritoneoscopy revealed a generalized carcinomatosis.

CASE 12. B. V. D. (B.M. U–395034), a 29-year-old unmarried woman, entered the hospital because of swelling of the abdomen of 2 months' duration. For 9 months her appetite had been poor. For about a year she had noted that she was easily fatigued and had not felt well enough to work. For many years she had taken large amounts of alcohol, including a quart of sherry daily, as well as some brandy.

On physical examination the liver was found to be markedly enlarged, extending 5 fingerbreadths below the costal margin. The spleen was also palpable about three fingerbreadths below the costal border. There was moderate ascites but no jaundice. The presumptive diagnosis was alcoholic cirrhosis.

Peritoneoscopy confirmed this diagnosis and showed the liver to be pale, mottled and yellow. A biopsy of the liver resulted in a diagnosis of acute alcoholic cirrhosis.

The patient was kept in the hospital for over a month, receiving a high-carbohydrate, high-protein and high-vitamin diet, parenteral liver therapy and several blood transfusions. The liver gradually became smaller, and the spleen hardly palpable. Peritoneoscopy was repeated at the end of 1 month's treatment, at which time the liver appeared essentially normal in size, with a brownish-red surface. A second biopsy showed less fat and definitely more fibrous tissue. Alcoholic hyalin was still present, but the process was much less acute.

In this case of moderate ascites with a presumptive diagnosis of alcoholic cirrhosis, peritoneoscopy gave positive confirmation of this diagnosis and when repeated at the end of a month demonstrated definite improvement as a result of treatment.

Other cases in this group in which ascites was a marked feature and in which the differential diagnosis of liver disease always presented itself may be briefly mentioned as follows:

CASE 13. O. N. (B.M. U–338963), a 41-year-old man, had ascites and hepatomegaly. Following resection of carcinoma of the sigmoid, x-ray examination demonstrated an enlarged liver and spleen with esophageal varices, making a clinical diagnosis of cirrhosis likely, although metastatic carcinoma was also a strong possibility.

Peritoneoscopy showed extensive carcinomatous implants in the liver and some possible implants on the peritoneum. A biopsy of the liver resulted in a diagnosis of metastatic adenocarcinoma.

This case was most unusual. In spite of the demonstration of esophageal varices, metastatic cancer of the liver rather than cirrhosis, was present.

CASE 14. H. G. (M.G.H. U–389058), a 62-year-old woman, had a history of diarrhea, loss of weight, anorexia and vomiting for 2 months. Physical examination showed the abdomen to be distended with fluid and a large, nodular mass in the epigastrium. Proctoscopy showed a nodular lesion, entirely submucosal. At peritoneoscopy 1500 cc. of yellow, blood-tinged fluid was aspirated. Because of a large omental mass, only a part of the liver could be seen, the anterior surface of

which appeared entirely normal. A large, pearly-gray mass with numerous excrescences on it was seen in the lower abdomen and pelvis. Several biopsies were obtained that resulted in a diagnosis of metastatic carcinoma of the peritoneum.

The patient went rapidly downhill and died, and autopsy confirmed the finding of widespread abdominal carcinomatosis arising in the stomach and involving the wall of the rectum and both ovaries. The liver was normal except for infarction.

CASE 15. G. L. (B.M. U–385439), a 59-year-old woman, had an abdomen distended with gas and fluid. A mass in the right side of the abdomen was thought from x-ray examination to be liver but clinically was apparently not related to the liver.

At peritoneoscopy 9000 cc. of yellow, bloody fluid, which was under pressure, was aspirated. The liver did not appear to be abnormal. The peritoneal surfaces throughout were studded with numerous implants that appeared typical of carcinoma. Several biopsies were obtained that showed the diagnosis to be metastatic spindle-cell sarcoma, possibly of ovarian origin.

CASE 16. M. S. O'B. (B.M. U–189703), a 70-year-old man, gave a history of enlargement of the abdomen for 1½ years, with several taps yielding grossly bloody fluid. There was no marked weight loss. In spite of a negative history of alcoholism, the presumptive clinical diagnosis was cirrhosis of the liver.

At peritoneoscopy 750 cc. of thin, bloody fluid was aspirated. The liver appeared normal. Occupying the entire left side of the abdomen was a reddish-purple mass, partly covered with omentum and appearing extremely vascular and cystic. Diagnosis at the conclusion of peritoneoscopy was a possible large splenic or omental cyst.

Laparotomy revealed a large hemangiosarcoma, probably of retroperitoneal origin, which was successfully removed. X-ray treatment was then given. A year and a half later the patient was doing well; peritoneoscopy was repeated and there was no evidence of recurrence.

Although liver disease was not seriously considered in the following case, ascites was the presenting symptom and cirrhosis had to be excluded.

CASE 17. D. L. (B.M. U–299241), a 49-year-old woman, had distention of the abdomen of 4 weeks' duration with anorexia, easy fatigability and loss of weight.

At peritoneoscopy 5000 cc. of straw-colored fluid was aspirated. The liver appeared normal. Multiple cystic implants from 1 to 2 mm. in diameter were seen on the peritoneum throughout the abdomen and pelvis. The examiner's diagnosis was abdominal carcinomatosis, probably of ovarian origin, but the biopsy report was tuberculosis.

Jaundice

In this group jaundice was the outstanding sign. Ascites and hepatomegaly were frequently present. The differential diagnosis included carcinoma of the liver, toxic cirrhosis, biliary cirrhosis, bile stasis, hepatitis or some other infectious process.

CASE 18. M. S. (B.M. U–351346), a 77-year-old woman, entered the hospital because of jaundice of 1 month's duration and weakness of 6 months' duration. There had been some pain in the right back, dating from a fall 8 months before admission. There was no history of alcoholism. The liver was not definitely palpable, but there was dullness four fingerbreadths below the right costal margin. The spleen was not palpable. There was no ascites. No esophageal varices were demonstrable by x-ray. Because of these findings, cirrhosis of the liver of ordinary type was thought to be unlikely and the presumptive diagnosis was carcinoma of the pancreas or biliary tract. A positive clinical diagnosis was impossible. A Graham test was negative. A bromsulfalein test showed 70 per cent dye retention.

Peritoneoscopy demonstrated a hobnail liver and a spleen enlarged to about twice the normal size. A biopsy of the liver resulted in a diagnosis of cirrhosis, unclassified.

In this jaundiced patient without a history of alcoholism, the most likely clinical diagnosis was thought to be malignancy, but peritoneoscopy revealed cirrhosis.

CASE 19. L. D. O'B. (B.M. U–396744), a 57-year-old woman, entered the hospital with a chief complaint of jaundice of 8 months' duration. Fourteen months prior to admission she had had a cholecystectomy at a local hospital. Six months later painless, progressive jaundice developed. She was operated on again at the same hospital and told that she had adhesions. The jaundice did not improve, and 3 months later she was again explored at the same hospital, with the same result. Although her appetite had been good, she had lost 60 pounds in 14 months.

Physical examination showed an intensively jaundiced patient with a hard, irregular mass involving the entire upper abdomen and extending into the right lower quadrant. Biliary cirrhosis following trauma to the common duct and carcinoma obstructing the biliary system was considered the most likely clinical diagnoses.

Peritoneoscopy showed the left lobe of the liver to be at the level of the umbilicus and the right lobe extended below the iliac crest. The surface throughout was smooth and grayish-black, with fine white mottlings and striations. No nodules were seen and there was nothing to suggest neoplasm in the liver. The spleen was not visible. A biopsy of the liver resulted in a diagnosis of biliary cirrhosis.

Exploratory laparotomy was later performed. The hepatic duct was found to end blindly and a vitallium tube was inserted to connect it with the duodenum.

In this severely jaundiced patient, peritoneoscopy excluded metastatic malignancy in the liver and established the diagnosis of biliary cirrhosis.

Doubtful Clinical Findings

CASE 20. A. M. (M.G.H. U–283167), a 35-year-old clerical worker, entered the hospital because of loss of appetite and easy fatigue. About 3 years before admission he had begun to have vague abdominal discomfort and epigastric fullness. Six months prior to admission he had been troubled with a slight cough productive of only a small amount of mucoid sputum.

Physical examination disclosed a large, firm mass in the left upper quadrant that was thought to be spleen. The liver was not felt. X-ray study of the chest demonstrated mottled, increased density in both upper lung fields, with a cavity in the right infraclavicular area. There was also some fine mottling in the left lower lung field. The films were interpreted as bilateral tuberculosis. One of the consultants believed that the x-ray picture, as well as the enlarged spleen might be explained on the basis of sarcoid.

Peritoneoscopy disclosed a spleen extending just below the level of the umbilicus, that was brown and smooth throughout except for three or four, grayish nodules of pinpoint size just above the splenic notch. The liver did not appear to be enlarged, but the anterior surface throughout both lobes was mottled with irregular, fine, gray striations. The capsule was extremely firm. A satisfactory biopsy, however, was obtained and the microscopic report was sarcoid.

In this case the presumptive clinical diagnosis was pulmonary tuberculosis and splenomegaly of undetermined cause. Peritoneoscopy showed that the whole process was due to sarcoid.

Primary Carcinoma of Liver

The following 5 cases of primary liver-cell carcinoma seem worth while reporting in some detail, as follows:

CASE 21. P. B. (M.G.H. U–150174), a 50-year-old man, entered the hospital complaining of upper-abdominal pain, epigastric distress, a weight loss of 25 pounds in 2 months and an upper-abdominal mass. The use of alcohol was denied.

Physical examination showed an irregular, hard, tender mass in the epigastrium, descending with respiration, which was probably liver. The spleen was not palpable. There was no jaundice or ascites. Esophageal varices were not demonstrable by x-ray. Since the mass in the epigastrium was so definitely tender and the patient was running a temperature up to 101 °F., a diagnosis of liver abscess or malignancy was considered and peritoneoscopy was undertaken.

At that time the liver presented a slightly mottled, cobblestone appearance in one area, but there was nothing to suggest liver abscess or carcinoma. The biopsy was possible hemangioma.

Since the patient continued to run a temperature, exploratory laparotomy was performed, which revealed an abscess well within the substance of the liver and therefore not visible by peritoneoscopy. The abscess cavity was drained and another biopsy of the liver resulted in a diagnosis of carcinoma. Two months later the patient died at another hospital, and autopsy confirmed the diagnosis of primary carcinoma of the liver.

CASE 22. M. G. (M.G.H. U–382144), a 46-year-old man, entered the hospital complaining of girdling pain around the abdomen, abdominal swelling, anorexia, vomiting and diarrhea. He was a moderate user of alcohol.

Physical examination disclosed a markedly distended, tense abdomen, with a fluid wave and shifting dullness in both flanks. The liver edge was palpable 7 cm. below the costal margin border; it was apparently smooth and extended across the midline into the left upper quadrant. The spleen was not palpable. Slight jaundice was present. Esophageal varices were not demonstrable by x-ray.

At the time of peritoneoscopy, 3000 cc. of slightly cloudy, yellow fluid was aspirated. The liver throughout both lobes was definitely hobnailed and thickened. On the anterior surface of the right lobe there were several yellowish areas that suggested neoplasm but were not typical. A biopsy was obtained from one of these areas, and the tissue appeared necrotic rather than malignant. Another biopsy was obtained from an area that appeared cirrhotic. The pathological report was toxic cirrhosis and hepatoma.

CASE 23. S. F. (M.G.H. U–300235), a 51-year-old man, entered the hospital with a history of having vomited about a quart of bright-red blood. He had been a known diabetic patient for 12 years. He had always used a considerable amount of alcohol. The liver was palpable two fingerbreadths below the right costal margin. The spleen was not palpable, nor was there any ascites or jaundice. Esophageal varices were not demonstrable by x-ray.

At peritoneoscopy the liver throughout both lobes showed multiple yellowish nodules, varying from 2 to 10 cm. in diameter. In fact, the liver seemed to be at least one third to one half infiltrated with tissue that looked carcinomatous. The biopsy was toxic cirrhosis with possible neoplasia.

Seven months later, the patient died at another hospital and autopsy showed toxic cirrhosis and primary carcinoma of the liver, with metastases to the portal, mesenteric and pancreatic lymph nodes.

CASE 24. D. J. C. (H.H. U–40-465), a 56-year-old man, entered the Huntington Memorial Hospital because of pain in the right upper quadrant, a severe chill, vomiting and loss of weight. He had been a heavy user of alcohol, especially before Prohibition, drinking "a dozen drinks a day."

Physical examination revealed a large mass filling the entire upper abdomen, having a tender, firm, smooth edge and moving with respiration, and questionable nodular areas in the epigastrium. The spleen was not palpable. There was slight jaundice and a small amount of abdominal fluid. No esophageal varices were demonstrable by x-ray.

At peritoneoscopy the liver throughout was studded with numerous whitish yellow, umbilicated lesions, varying from 2 to 5 cm. in diameter, many of them coalescing. The right lobe of the liver was almost completely replaced with tissue that had the appearance of carcinoma. About 2000 cc. of yellow fluid was aspirated. A biopsy of the liver resulted in a diagnosis of carcinoma, unclassified. About 2 weeks later the patient died and autopsy revealed primary bile-duct carcinoma of the liver with metastases to the periportal and peripancreatic lymph nodes.

CASE 25. L. W. H. (P.D.H. U–8211), a 72-year-old man, entered the Pratt Diagnostic Hospital complaining of pain in the right upper quadrant, nausea and vomiting, weakness and loss of weight. He had been a moderate user of alcohol all his life.

Physical examination revealed at least three distinct masses within the abdomen. The first, taken to be liver, descended with respiration about four fingerbreadths below the right costal margin. The edge was sharp and irregular and definite tender nodules were palpated along its border. Below this was a round, extremely hard mass to the right of the midline, extending approximately to the level of the umbilicus. In the right flank a round, smooth, hard, slightly nodular mass was felt below the liver. The spleen was not p lpable. There was no jaundice or ascites. Esophageal varices were not demonstrable by x-ray.

Peritoneoscopy disclosed a comparatively normal left lobe of the liver, but the edge of the right lobe was markedly rounded and contained a yellow nodule 3 to 4 cm. in diameter, consistent with carcinoma. Farther in the right flank, but continuous with the liver and more posteriorly, was a hard, gray, nodular mass, consistent with carcinoma invading the liver. There was another mass occupying the right upper quadrant below the liver, apparently distinct from the liver and covered entirely by omentum. A biopsy of the mass in the right flank resulted in a diagnosis of primary liver-cell tumor.

These 5 cases of proved hepatoma present certain features of interest. All the patients were men in middle or late life. All except one had used alcohol in moderate to large amounts. The only one who denied the use of alcohol was a native-born Armenian who may have been exposed to some unusual liver disease. All except one complained of upper abdominal pain, usually in the right upper quadrant or epigastrium. Loss of weight and vomiting were noted in 3 cases.

In all cases physical examination showed an upper abdominal mass, usually of considerable size and frequently thought to be somewhat nodular. The spleen was not palpable in any case, nor were esophageal varices ever demonstrable by x-ray. Jaundice and ascites were present in 2 cases.

The biopsies obtained at peritoneoscopy were positive in 2 cases for hepatoma, in 1 case for carcinoma (unclassified), and in 1 for toxic cirrhosis with possible neoplasia. There was some difference of opinion among the pathologists in the fourth case, and it was thought that if carcinoma were present it was primary hepatoma. In the fifth case, the neoplastic areas were not demonstrable by peritoneoscopy, owing to adhesions and also to the fact that the neoplasm was within the substance of the liver.

Heretofore it has always been impossible to make a positive clinical diagnosis of primary carcinoma of the liver, but with the aid of the peritoneoscope a positive diagnosis is now possible.

DISCUSSION

Since the division of these cases into groups is obviously arbitrary, it may be as well to discuss all of them together. It is evident that peritoneoscopy

is a procedure that is of great importance and that by this method alone many doubtful clinical diagnoses can be positively established and some others entirely changed. Peritoneoscopy may be safely performe: in many patients on whom one would hesitate to do a laparotomy or where a laparotomy would be too formidable a procedure for the information obtainable.

Is metastatic cancer present in the liver? Its presence or absence may change the treatment entirely. Given a large nodular mass in the epigastrium it may be assumed clinically to be cancer in the liver, but peritoneoscopy may show that the mass does not involve the liver; it may be a large carcinoma of the stomach that can be successfully resected. Conversely, a nonpalpable liver may contain metastatic cancer demonstrable by peritoneoscopy and a laparotomy may thus be avoided.

The fact that a liver is large is interesting and important, but what does it mean? Liver-function studies may show good or bad function, but still one does not know the diagnosis until a biopsy is performed. Many times I have been surprised to find cirrhosis when I suspected cancer, and vice versa; and at other times cancer is superimposed on cirrhosis. Occasionally, sarcoma is found instead of cirrhosis. Sometimes when liver disease has been suspected, peritoneoscopy has revealed a large, normal liver, ovarian carcinomatosis, hemangiosarcoma or tuberculous peritonitis. Moreover, by getting liver biopsies in cirrhosis before and after treatment, it is possible to watch the progression or regression of the process, and thus evaluate the therapeutic procedures. The differential diagnosis of patients with ascites or jaundice, or both, is often difficult, but by direct endoscopic inspection the problem frequently is easily solved. A rare diagnosis, such as sarcoid of the liver, may occasionally be made by peritoneoscopy. Primary liver-cell carcinoma can be positively diagnosed by peritoneoscopic biopsy.

Conclusions

Peritoneoscopy is an important and well-established method of examining the peritoneal cavity that is especially applicable to the differential diagnosis of liver disease. With biopsy, a suspected diagnosis is made positive.

In a series of peritoneoscopies in 435 patients, the examination was undertaken primarily to study the liver in over two thirds of the cases. One hundred and seventy patients were found to have metastatic carcinoma, 73 had cirrhosis, and the remainder had various diseases, including hepatoma, sarcoma, lymphoma, lymphangioma, Banti's disease, cholangitis, polycystic liver, echinococcal cyst and sarcoid.

References

1. Benedict, E. B. Peritoneoscopy. *New Eng. J. Med.* 218:713-719, 1938.
2. *Idem.* Value of peritoneoscopy in gastro-enterology: review of 100 cases. *Am. J. Digest Dis.* 6:512-519, 1939.
3. *Idem.* Peritoneoscopy. Chapter in *Oxford Medicine*, 1942. Pp. 122 (35-44).
4. Ruddock, J. C. Peritoneoscopy. *West. J. Surg.* 42:392-405, 1934.
5. *Idem.* Peritoneoscopy. *Surg., Gynec. & Obst.* 65:623-639, 1937.

DICUMAROL THERAPY IN THROMBOTIC EMERGENCIES*

JAMES A. EVANS, M.D.†

BOSTON

SINCE August, 1941, it has been the policy at the Lahey Clinic to treat thrombotic emergencies by one or more of the following three relatively new methods: paravertebral procaine sympathetic block,[1] venous section and ligation,[2] and anticoagulant therapy with Dicumarol, with or without heparin.[3] Procaine sympathetic block is reserved for patients with thrombophlebitis (phlegmasia alba dolens) in whom swelling exists, in order to abolish constrictor reflexes, promote arteriolar pulsation, enhance oxygenation, restore normal capillary pressure, and thus reduce edema. Sympathetic block probably has no influence on the prevention of pulmonary embolism.

Because of the probable efficacy of anticoagulation therapy in the prevention of postoperative embolism, venous section and ligation are reserved for patients with phlebothrombosis who are over fifty years of age and who have had a warning benign embolism. This rule is not absolute, however, even in these cases, and the procedure has been resorted to only four times since October, 1941. So far there has been no fatality and only one recognizable recurrent benign pulmonary embolism among 46 patients with postoperative venous thromboses treated by anticoagulation therapy, all of whom were candidates, in varying degree, for pulmonary embolism. The phrase "in varying degree" is used advisedly because only 23 of these patients fell into the group with postoperative benign embolism, who are notoriously likely to develop subsequent benign or fatal emboli. We do not hesitate to employ venous section and ligation in patients with a history of multiple pulmonary emboli, postoperative or otherwise, but we advise a prolonged course of anticoagulation therapy after ligation when there is a likelihood of continuing active phlebitis and formation of venous thrombi. This is considered necessary because at autopsy venous thrombosis has been seen to extend above the point of section and ligation and to constitute the source of further pulmonary emboli, although severance of the vein was at a point above the level of the clot.

A rational use of these three methods, either singly or combined, was the subject of another paper.[4]

Anticoagulant therapy by heparin alone is expensive for the patient and tedious and laborious for the professional staff, but with the advent of Dicumarol, which can be given by mouth, there is available a cheap and easy preventive of intravascular clotting. However, heparin is now being given the first two to five days to cover the immediate emergency period before Dicumarol has caused a fall in the prothrombin percentage.

CLINICAL USE OF DICUMAROL

The advantages of anticoagulation therapy with Dicumarol were discussed in statistical studies by Allen, Barker and Waugh.[5] The experience at the Lahey Clinic, as outlined in this paper, corroborates their conclusions. In addition, I wish to point out the danger of hemorrhage and even death in the use of this potent hemorrhagic agent.

The isolation of Dicumarol (3,3′-methylenebis, 4-hydroxycoumarin), the active principle of spoiled sweet clover causing hemorrhagic disease of cattle, by Link and his associates[6–9] at the Wisconsin Agricultural Experiment Station at the University of Wisconsin and the pioneer clinical work by Meyer and his associates[10, 11] and of Butt, Allen and Bollman[12] are examples of excellent pharmaceutical and clinical research. The scientific curiosity of a veterinarian, Roderick,[13] prompted the development of this new drug after Quick[14] proved that its action on the clotting mechanism is due to the lowering of the prothrombin content of the blood. Whether this action is due to the inhibition of the formation of prothrombin in the liver or in the blood stream is unknown. Butt, Allen, Bollman and Preston[12, 15] have shown that intravascular clotting is delayed when the prothrombin time is prolonged by Dicumarol.

I have found, as have other investigators,[5, 10–12, 15, 16, 17, 18] that Dicumarol has no consistent effect on the platelets, hemoglobin, red-cell count, white-cell count, capillary fragility, clot retraction, serum calcium or fibrinogen. The clotting time was prolonged only when the prothrombin time was reduced to low levels, usually around 40 per cent of normal.

REGULATION OF DOSAGE

After trying various doses of Dicumarol, an initial dose of 300 mg. for a patient below 120 pounds and 400 mg. for one over 120 pounds was adopted. A daily maintenance dose of 100 to 300 mg. was administered, depending on the rapidity of the fall of the prothrombin time. The average total amount required to maintain the prothrombin time below 75 per cent‡ was 1200 mg. in eight days. When the

*From the Department of Internal Medicine, Lahey Clinic. Read in part before the Boston Surgical Society, April 26, 1943.

†Member, Department of Internal Medicine, Lahey Clinic.

‡The prothrombin time is expressed in percentage of normal because the rate of clotting of the blood, when carried out according to the method described by Quick,[14] appears to be proportional to the amount of prothrombin in the blood. Accordingly, the prothrombin values are based on the clotting time of the patient's blood divided by the clotting time of a specimen of normal blood. If the thromboplastin proved to be too active, the patient's and control's serums were diluted with saline solution.

prothrombin time fell below 60 per cent or fell precipitously, the drug was discontinued. These doses of Dicumarol were given regardless of whether heparin was administered simultaneously. Heparin administration in itself may cause a fall of the prothrombin percentage to around 75 per cent of normal and does not necessitate stopping the Dicumarol. The administration of heparin is guided by the clotting time, Dicumarol by the prothrombin percentage.

One of the greatest difficulties in Dicumarol therapy is the determination of the amount of Dicumarol necessary to obtain the desired effect on prothrombin time. The maximum dose in this series was 3300 mg. in fourteen days, which was followed by reduction of the prothrombin time from 89 to 35 per cent. The minimum dose was 576 mg. in two days, reducing the prothrombin time from 78 to 27 per cent. The prothrombin time may continue to drop as long as five days after the drug is discontinued. Bleeding may occur with the prothrombin percentage below 40. The latent period of Dicumarol varied from one to six days. In combined heparin and Dicumarol therapy, therefore, it may be necessary to administer heparin longer than the average two-day period. Of 56 patients receiving Dicumarol, 5 who had adequate doses gave no response. Two of these were also heparin resistant. Others have noted this phenomenon in postoperative venous thrombosis, which is sometimes accompanied by a rise in platelet count and prothrombin time, and may indicate true hyperprothrombinemia. One of the patients exhibited irreversible shock and bloody pulmonary edema in spite of adequate replacement of blood loss by transfusion.

Precautions To Be Observed

The following precautions should be observed: Dicumarol should not be given to patients with hepatic damage, especially if reduction in prothrombin percentage has already occurred. Its use is contraindicated in any case of hemorrhagic diathesis except in those cases in which it is considered certain that splenectomy will cure the condition. The morning prothrombin time should be determined before the daily afternoon dose of Dicumarol is given.

The typical course of a case under combined Dicumarol therapy and heparin is shown in Figure 1. The source of the pulmonary embolism was thought to be a pelvic phlebothrombosis following surgical resection of a carcinoma of the right ovary with side-to-side anastomosis around a carcinoma of the sigmoid. A thirty-six-hour latent period in the action of Dicumarol was evident. When heparin was discontinued, the Dicumarol effect was maintained for at least seven days. The patient was allowed to get out of bed without incident nine days after the occurrence of pulmonary embolism.

If the patient's surgical condition permits, he may sit up when the prothrombin percentage is below 70. Of this series of venous thrombotic patients, 68 per cent were out of bed without untoward incident within two weeks of recognition of the original vascular accident.

Table 1 gives the varieties of thrombotic emergencies found in the patients receiving Dicumarol either alone or combined with heparin in the nineteen-month period (August, 1941, to April, 1943).

Table 1. *Diagnoses in 56 Cases Treated with Dicumarol Alone or Combined with Heparin.*

Diagnosis	No. of Cases
Postoperative venous thrombosis with pulmonary embolism	23
Postoperative venous thrombosis without pulmonary embolism	19
Thrombophlebitis 13	
Phlebothrombosis (2 with femoral ligation) 6	
Venous thrombosis or embolism complicating previous operation (prophylactic)	6
Suspected pulmonary embolism (later course proved doubtful)	1
Suspected venous thrombosis (later course proved doubtful)	1
Prophylaxis (after splenectomy)	1
Arterial embolism	2*
Coronary occlusion	1
Dissecting aneurysm of aorta (mistaken for pulmonary embolism)	1
Superficial phlebitis migrans	1
Thrombosis of lateral sinus and rolandic vein with right hemiplegia and partial aphasia	1
Total	56

*One of these cases is also included in "postoperative venous thrombosis without pulmonary embolism."

Results of Dicumarol Therapy

During the nineteen-month period, 46 patients with venous thrombosis or a history of venous thrombosis were treated with Dicumarol (Table 2). Thirty of these patients also received heparin. Six of them also had paravertebral sympathetic procaine block. None had venous division and ligation.

Table 2. *Data in 46 Cases of Postoperative Venous Thrombosis.*

Reason for Anticoagulant Therapy	Number of Cases	Subsequent Thrombosis	Subsequent Embolism	Subsequent Fatal Embolism
Postoperative pulmonary embolism or infarction	23	0	1	0
Postoperative venous thrombosis	17*	0	0	0
Venous thrombosis or embolism complicating previous operation	6	0	1	0
Totals	46	0	2	0

*Thirteen of these patients had thrombophlebitis; the other 4 had phlebothrombosis.

I have divided these cases, as did Allen, Barker and Waugh[8] at the Mayo Clinic, into three groups: postoperative pulmonary embolism or infarction, postoperative venous thrombosis, and venous thrombosis or embolism complicating previous operation. These authors compared the expected number of emboli in untreated patients with the actual number that occurred under Dicumarol therapy, their expectancy figures being those prepared by Barker and his associates.[19] It is doubtful whether such

expectancy figures can be applied with accuracy to patients in another clinic with different hospital and surgical routines and under different climatic conditions. Since such expectancy figures from the Lahey Clinic have not been compiled on account of embolism occurred. In none of the 46 patients with venous thrombosis did additional foci of thrombophlebitis or phlebothrombosis become evident once treatment was begun. Of the 40 patients in whom venous thrombosis occurred after operation,

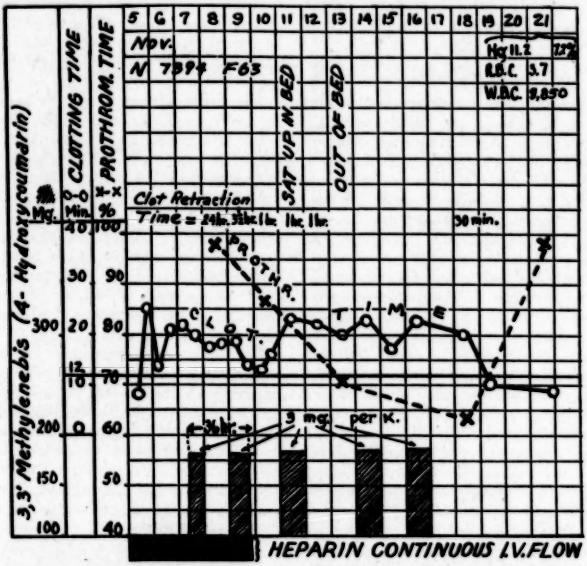

FIGURE 1. *Course of a Case under Combined Dicumarol and Heparin Therapy.*

the pressure of wartime work, all that can be reported is that only 1 subsequent benign and no subsequent fatal embolism were encountered in 23 patients with postoperative pulmonary embolism treated with heparin combined with Dicumarol. The embolism occurred when the prothrombin time was reduced to 55 per cent.

In 17 cases of postoperative venous thrombosis uncomplicated by embolism at the time of beginning anticoagulation therapy, no pulmonary embolism occurred. Since phlegmasia alba dolens is rarely a cause of pulmonary embolism, this group has been subdivided into 13 cases of thrombophlebitis and 4 of phlebothrombosis. All observers in this field realize that other silent foci of phlebothrombosis often occur in thrombophlebitis and give rise to pulmonary embolism, well justifying the protection of such patients. Also, my experience has shown that anticoagulation therapy greatly shortens the morbidity period from phlegmasia alba dolens.

In 6 patients with a history of thrombophlebitis or embolism following a previous operation, no with or without pulmonary embolism, 9 were out of bed one week or less after the initial vascular accident was recognized, and 27 within two weeks.

TABLE 3. *Complications in 56 Cases.*

	No. of Cases	Per Cent
Deaths:		
Directly ascribable to Dicumarol	2	4
Hemorrhage into wound, retroperitoneal tissues and mesentery, and bloody pulmonary edema	1	
Dissecting aneurysm mistaken for pulmonary embolism, hemorrhage into stomach	1	
Not directly ascribable to Dicumarol	2	
Perforated gall bladder	1	
Gangrene of both legs (saddle embolism)	1	
Hemorrhages:	8	14
Into wound (1 fatal and 1 saved by transfusion)	2	
Into stomach (fatal)	1	
Hematoma in buttock	1	
Mild epistaxis	1	
Hematuria and bleeding from gums	1	
Hematuria, epistaxis and bleeding from gums	1	
Hemoptysis	7	
Total	12	18

Among the 46 patients with venous thrombosis no fatal pulmonary embolism occurred.

COMPLICATIONS

Of the 4 deaths occurring during Dicumarol therapy (Table 3), 2 can be attributed to hemor-

rhage, the result of lowered prothrombin content of the blood.

The first death occurred following a second-stage sympathectomy for chronic deep femoral thrombophlebitis. Venograms before and after spinal anesthesia had demonstrated a spastic element. Following the first-stage sympathectomy, Dicumarol was given successfully. The prothrombin time was allowed to return to normal before the second stage was done, after which Dicumarol was again administered. The second daily dose of the second course of Dicumarol was given before that morning's prothrombin time was determined. By the third morning the prothrombin time had dropped to 37 per cent, after 688 mg. of Dicumarol had been given in two days. The patient had signs of hemorrhage and shock, and six transfusions failed to save her life. Autopsy showed hemorrhage into the abdominal wall, retroperitoneal tissues and wound and bloody pulmonary edema.

The second death due to hemorrhage occurred in a patient with a dissecting aneurysm of the aorta, which was proved at autopsy but was mistaken during life for a postoperative pulmonary embolism. Three daily doses of Dicumarol — 400, 200 and 100 mg., respectively — were given, the prothrombin time falling precipitously from 100 to 54 per cent in three days. By the fourth day, without further Dicumarol, the prothrombin time fell to 33 per cent, where it remained for the next five days, when the patient was allowed to sit up. Six days after the last dose of Dicumarol, the prothrombin time suddenly fell to 11 per cent. The only sign of hemorrhage was moderately bloody urine whose source was a transurethral resection that had been performed three weeks before. Because of the low prothrombin level, a transfusion was given, but death occurred suddenly three hours later, with blood exuding from the patient's mouth and nose. Autopsy showed petechial hemorrhages into the pericardium, a gastric mucosa oozing blood, a stomach full of blood and regurgitation of blood into the esophagus. No communication between the dissecting aneurysm and the esophagus or stomach could be found. This patient would undoubtedly have died of the dissecting aneurysm, but perhaps under other circumstances might have been saved by repeated transfusions.

The third death was due to a perforated gall bladder, and the fourth to gangrene of both legs from saddle embolism.

Table 3 gives a summary of the hemorrhagic accidents in the total series of 56 patients. Transfusion was necessary in 3 cases. There were 2 deaths directly ascribable to Dicumarol (4 per cent) and 8 cases with hemorrhage (14 per cent).

Summary and Conclusions

Fifty-six patients with thrombotic emergencies were treated by Dicumarol or Dicumarol combined with heparin as anticoagulants between August, 1941, and April, 1943. Two deaths occurred (4 per cent), 1 of which can be attributed unequivocally to Dicumarol poisoning and hemorrhage. Hemorrhagic phenomena were evident in 8 cases (14 per cent). These complications emphasize the dangers and disadvantages of Dicumarol therapy, but the obvious advantages to date appear to outweigh the dangers of this preventive method if adequate laboratory facilities are available and proper precautions are observed.

The principal precaution to be observed is the determination of the morning prothrombin time before ordering the daily maintenance dose of Dicumarol.

The combined use of heparin and Dicumarol is considered safe only if the doses of heparin are controlled by twice-daily determinations of the coagulation time of the blood, and the doses of Dicumarol by daily determinations of the prothrombin time.

One benign and no fatal pulmonary embolism occurred in a series of 46 cases of venous thrombosis treated by the anticoagulant Dicumarol, alone or combined with heparin.

This series of 46 cases of thrombophlebitis is not large enough to draw the conclusion that venous ligation is an unnecessary procedure. If a patient is over fifty and has had a warning benign pulmonary embolism, therefore, venous ligation is still indicated. If statistical proof can be accumulated from other workers in this field, venous ligation may prove unnecessary except in rare cases of recurrent emboli occurring in spite of anticoagulation therapy.

605 Commonwealth Avenue.

References

1. Ochsner, A., and DeBakey, M. Treatment of thrombophlebitis by novocain sympathetic: technique of injection. *Surgery* 5: 491-497, 1939. Therapeutic considerations of thrombophlebitis and phlebothrombosis. *New Eng. J. Med.* 225:207-227, 1941.
2. Homans, J. Exploration and division of femoral and iliac veins in treatment of thrombophlebitis of leg. *New Eng. J. Med.* 224:179-186, 1941.
3. Evans, J. A. Combined use of heparin and dicoumarin (3,3' methylenebis, 4-hydroxycoumarin) in thrombophlebitis and pulmonary embolism (preliminary report). *Lahey Clin. Bull.* 3:248-256, 1942.
4. Evans, J. A. Orientation of treatment in thrombophlebitis, phlebothrombosis and pulmonary embolism. *Ann. Int. Med.* 17:970-974, 1942.
5. Allen, E. V., Barker, N. W., and Waugh, J. M. Preparation from spoiled sweet clover [3,3'-methylene-bis-(4-hydroxycoumarin)] which prolongs coagulation and prothrombin time of blood: clinical study. *J. A. M. A.* 120:1009-1015, 1942.
6. Campbell, H. A., Roberts, W. L., Smith, W. K., and Link, K. P. Studies on hemorrhagic sweet clover disease. I. Preparation of hemorrhagic concentrates. *J. Biol. Chem.* 136:47-55, 1940.
7. Campbell, H. A., Smith, W. K., Roberts, W. L. and Link, K. P. Studies on hemorrhagic sweet clover disease. II. Bioassay of hemorrhagic concentrates by following prothrombin level in plasma of rabbit blood. *J. Biol. Chem.* 138:1-20, 1941.
8. Campbell, H. A., Smith, W. K., Overman, R. S., and Link, K. P. Studies on hemorrhagic sweet clover disease. III. Variations of response of rabbits to hemorrhagic hay. *J. Agric. Res.* (in press).
9. Campbell, H. A., and Link, K. P. Studies on hemorrhagic sweet clover disease. IV. Isolation and crystallization of hemorrhagic agent. *J. Biol. Chem.* 138:21-33, 1941.
10. Bingham, J. B., Meyer, O. O., and Pohle, F. J. Studies on hemorrhagic agent 3,3'-methylenebis (4-hydroxycoumarin). I. Its effect on prothrombin and coagulation time of blood of dogs and humans. *Am. J. M. Sc.* 202:563-578, 1941.
11. Bingham, J. B., Meyer, O. O., and Howard, B. Studies on hemorrhagic agent 3,3'-methylenebis (4-hydroxycoumarin). III. Report on further clinical observations. *Am. J. M. Sc.* 205:587-594, 1943.
12. Butt, H. R., Allen, E. V., and Bollman, J. L. Preparation from spoiled sweet clover [3,3'-methylene-bis-(4-hydroxycoumarin)] which prolongs coagulation and prothrombin time of blood: preliminary report of experimental and clinical studies. *Proc. Staff Meet., Mayo Clin.* 16:388-395, 1941.
13. Roderick, L. M. Problem in coagulation of blood: "sweet clover disease of cattle." *Am. J. Physiol.* 96:413-425, 1931.

14. Quick, A. J. Coagulation defect in sweet clover disease and in hemorrhagic chick disease of dietary origin: consideration of source of prothrombin. *Am. J. Physiol.* 118:260-271, 1937.
15. Bollman, J. L., and Preston, F. W. Effects of experimental administration of dicoumarin; 3,3'-methylene-bis-(4-hydroxycoumarin). *J. A. M. A.* 120:1021-1024, 1942.
16. Wright, I., and Prandoni, A. Dicoumarin 3,3'-methylene-bis-(4-hydroxycoumarin): its pharmacologic and therapeutic action in man. *J. A. M. A.* 120:1015-1021, 1942.
17. Butsch, W. L., and Stewart, J. D. Clinical experiences with dicoumarin; 3,3'-methylene-bis-(4-hydroxycoumarin). *J. A. M. A.* 120:1025, 1942.
18. Editorial. Antiprothrombin therapy. *J. A. M. A.* 120:1040, 1942.
19. Barker, N. W., Nygaard, K. K., Walters, W., and Priestley, J. T. Statistical study of postoperative venous thrombosis and pulmonary embolism. III. Time of occurrence during postoperative period. *Proc. Staff Mtgs., Mayo Clin.* 16:17-21, 1941.

ABSCESS OF THE SPLEEN*

IRVING NORMAN WOLFSON, M.D.†

NEW YORK CITY

ABSCESS of the spleen has attracted little attention in the American literature. Although excellent reviews and case reports have been published by Elting,[1] Inlow,[2] Billings,[3] and Walker[4] and recently by Lemmon and Paschal,[5] the European literature on the subject is much more extensive. This is unfortunate, for, although splenic abscess is not of frequent occurrence, its diagnosis is not difficult when kept in mind. Furthermore, the correct therapeutic approach greatly reduces an extremely high mortality rate (80 to 100 per cent[2, 6]).[2, 3] It would be most unfortunate, therefore, if the diagnosis were missed simply because the possibility had not been considered. Splenic abscess occurred in 0.4 per cent of autopsies at the Boston City Hospital, according to Walker,[4] and Billings[3] reported 24 cases in 3600 autopsies, an incidence of 0.7 per cent.

The classification of splenic abscesses has been simplified since Kuttner[7] outlined seven varieties in his classic paper on the subject. Three major modes of pathogenesis are now generally recognized.

Traumatic abscesses constitute an estimated 15 per cent of all splenic abscesses. Clinically they result from trauma to the organ, with a resultant perisplenic hematoma. Under such conditions, the hematoma forms a point of lessened resistance, and is subject to suppuration whenever there occurs a bacteremia resulting from major or minor infective processes. Experimentally, splenic abscesses have been produced by Caldarera,[8] who rendered animals' spleens susceptible by traumatizing them and injected *Staphylococcus aureus*. Kuttner[7] similarly produced abscesses of the spleen. In 1927, Inlow reviewed 23 cases of traumatic abscess and discussed one of his own. He found that conservative treatment of these cases resulted in a mortality of 100 per cent, whereas with surgical intervention this figure was reduced to 38 per cent.

Abscess of the spleen occasionally results from extension of a neighboring pathologic process. Thus, infected colonic or gastric neoplasms may invade the spleen, or left subphrenic collections may erode into it so that the organ forms the floor of the abscess cavity. In a case seen at the Mount Sinai Hospital, a large abscess was found in a spleen invaded by lymphosarcomatous tissue. Most such cases are of only academic interest, since the patient is usually suffering from a serious condition to which the splenic abscess is secondary and drainage of the abscess would be of no therapeutic benefit.

The most important group of splenic abscesses are those resulting from metastatic spread of infection elsewhere. Thus, furunculosis, erysipelas, otitis media, and femoral thrombophlebitis, as well as appendicitis and salpingitis, have preceded development of abscess of the spleen. It is important to divide this group into those cases in which the infection spreads along venous channels, and those in which the infection reaches the spleen through the splenic artery. Cases in the first group, which includes the case presented below, usually result from intra-abdominal suppuration. Cases that come to autopsy usually show pylephlebitis and thrombophlebitis of the splenic vein. Thus, Fauntleroy[9] reported a case following acute appendicitis in which autopsy revealed three splenic abscesses with thrombosis of the splenic vein and with numerous small necrotic areas in the liver. Cooke[10] found a large and septic spleen with purulent thrombophlebitis of the mesenteric and splenic veins resulting from a perforated colonic diverticulum. Such cases tend to have a serious prognosis because of the associated venous lesions.

The large number of cases resulting from suppuration elsewhere are probably due to spread of infection by way of the splenic artery. In this group must belong Walker's[4] case, with streptococcal sepsis resulting from thrombosis of the lateral sinus secondary to mastoiditis; Billings's[3] case, in which *Staph. aureus* was cultured from a recently incised carbuncle of the neck as well as from the splenic abscess; Cutler's[11] case, which was preceded by otitis media; Eliason's[12] case, in which a staphylococcal sepsis and splenic abscess followed a peritonsillar abscess; and the case of Lemmon and Paschal,[5] in which a splenic abscess was preceded by thrombophlebitis of the femoral vein. In these cases, it is apparent that the infecting material must have traversed the lesser circulation and escaped the pulmonary network in order to reach the spleen. The only alternative pathway is through a congenital

*From the Medical Service of Dr. George Baehr and the Surgical Service of Dr. Harold Neuhof, Mount Sinai Hospital, New York City.

†Intern, Mount Sinai Hospital.

cardiac defect. In most cases, however, no cardiac murmurs indicative of such a lesion are described.

Special mention should be made of the group of cases described by Rabin and Moolten.[13] These observers reported 5 cases of lung abscess from which splenic abscess developed—presumably by way of the splenic artery. In each case, infection of a branch of the splenic vein occurred at the site of the abscess and eventually resulted in fatal pylephlebitis.

Metastatic splenic abscess may develop clinical manifestations from one day to several months after the appearance of the primary source. The onset is often heralded by sudden severe pain in the left hypochondrium, although the pain may also be of gradual onset. On the other hand, when a large abscess is buried in the middle of the spleen, there may be no pain referred to the splenic region, as in Fauntleroy's[9] case. It is usually stated that abscesses of the upper pole of the spleen give rise to pleuritic pain, with inspiratory increase of the pain and occasional radiation to the left shoulder, whereas abscesses of the lower pole give rise to peritoneal signs. In general, this is true, but it should be noted that in May's[14] case a superior pole abscess ruptured into the peritoneal cavity. Accompanying the pain are the general symptoms of severe infection—temperature, usually spiking, chills and leukocytosis. The temperature generally reaches 103°F. or more, but in Lemmon and Paschal's[5] case it remained below 100 before drainage of the abscess. Similarly, the white count may reach 20,000 to 30,000 but in several cases has been below 10,000. It is apparent, therefore, that splenic abscess should be suspected in any patient with pain in the left upper quadrant of the abdomen, especially if an adequate previous focus of infection is found or if there are any symptoms or signs of sepsis.

Physical examination usually discloses tenderness and spasticity in the left upper quadrant, and careful observation may reveal edema of the soft parts overlying the spleen and even a tense, glistening skin. The spleen is almost always enlarged, and is usually felt clinically. There may be signs of fluid in the left pleural cavity, and radiologic examination may disclose this, with or without elevation of the left leaf of the diaphragm.

Splenic puncture as a diagnostic measure has been both supported and condemned. The procedure is obviously not without danger. In doubtful cases, however, it is useful. The safest policy is to restrict its use to such cases and to have the puncture performed in the operating room, with all preparations made for splenotomy or splenectomy. If pus is aspirated, the needle should be left in place until the spleen is exposed. In this way, the danger of producing empyema by introducing pus along the track of the needle is obviated.

If untreated, splenic abscesses run a severe septic course. A few become chronic, with sterile pus, and produce few symptoms. The overwhelming majority, however, rapidly go on to a fatal termination if surgical intervention is not instituted. The procedure employed may be splenectomy or splenotomy. Splenotomy is usually preferred unless the organ is easily mobilizable and free of adhesions, when splenectomy may be indicated. Of 55 cases gathered by Billings,[3] splenotomies were performed in 51, with 7 deaths, and splenectomies in 4, with 3 deaths. Splenotomy may be performed through a transpleural, transperitoneal or retroperitoneal approach. This varies with the site of the abscess, as well as with the preference of the surgeon.

In those cases in which suppuration is localized in the spleen, surgical intervention produces a cure in the majority. Operation is contraindicated in cases of splenic abscess resulting from subacute bacterial endocarditis, in which the prognosis is necessarily the grave one of the underlying disease. Similarly, surgery cannot offer much hope when the abscess is secondary to extensive pyemia with multiple suppuration elsewhere, for in such cases the splenic lesion is an incidental and unimportant finding. When the splenic abscess is the result of, or causes, suppurative splenic and portal thrombophlebitis, the prognosis is usually grave, but surgery offers the patient a slight chance, especially if splenectomy with ligation of the purulent vein can be performed. Such a case, with an unsuccessful result, is reported below.

Of 30 cases of splenic abscess described by Walker[4] from autopsy material, 22 had abscesses involving other organs, leaving only 8 that could be benefited by surgery. Since this series included only cases seen at autopsy, patients diagnosed clinically as splenic abscess have a higher percentage of operability.

Case Report

A 27-year-old woman bookkeeper (501064), was admitted to the Mount Sinai Hospital on January 30, 1943. Six weeks before admission, she had an appendectomy with drainage at another hospital, because of a 2 weeks' illness characterized by abdominal pain, fever and pharyngitis. The removed appendix was reported as showing periappendicitis. Three weeks postoperatively, the patient was discharged well, but on the same day she developed shaking chills, fever up to 105°F. and sweats. One week after discharge she returned to the hospital, where she continued to have high fever and sweats, without localizing symptoms. After 2 weeks she was transferred to the Mount Sinai Hospital.

Physical examination on admission revealed an acutely ill woman. The temperature was 105.0°F., the pulse 130, the respirations 30, and the blood pressure 110/58. The eyes, ears, nose and throat were normal. Examination of the lungs disclosed an impaired percussion note and diminished breath sounds at the left base. There were no rales. The heart was not enlarged. There was a short systolic murmur at the apex, and embryocardiac rhythm was noted. In the right lower quadrant of the abdomen was a wound draining a minimal amount of mucopurulent material. The liver was barely palpable, and under the left costal cage a definite tender mass was felt. Both costovertebral angles were tender, and there was a suggestion of a bulge on the left. The white-cell count on admission was 30,000, with 95 per cent neutrophils. The urine showed a trace of albumin and a few granular and cellular casts. A blood culture taken on admission was later re-

ported as positive for beta-hemolytic streptoccocus. X-ray examination of the chest showed a small amount of fluid in the lower portion of the left pleural cavity. There was no elevation of the diaphragm.

The day after admission, the left side of the chest was tapped. The 10th interspace was entered at one third of the distance from the posterior axillary line to the spine. Superficially, after penetration for a short distance, thin sanguinous fluid was obtained. The needle was inserted deeper, and at a depth of 5 cm. pure pus was obtained, from which beta-hemolytic streptococci were grown. The patient was therefore removed to the operating room.

The report of the surgeon (Dr. Harold Neuhof) follows:

> Aspiration at the level of the 10th interspace revealed pus. The needle was left in place and the 11th interspace was aspirated. Here sanguinous fluid was obtained. A preoperative diagnosis of splenic abscess with rupture of the spleen was made.
>
> Accordingly, the 11th rib was liberally excised. The pleural cavity, which was free of fluid but potentially infected by aspiration, was traversed and an upward bulge of the diaphragm toward the midline was noted. General anesthesia was administered, local anesthesia having been employed up to this point. The diaphragm was sutured to the margins of the thoracic wound and was then incised, its edges being pulled up to the surface and sutured over the first layer in order to shut off completely the free pleura. This was achieved down to the posterior part of the wound, at which place a tube was inserted for drainage of the potentially infected pleura. The collection of pus was opened up and was found to be partly within and partly outside of the spleen. The latter was found to be split in two. There was then evacuated a considerable collection of old fluid blood from beneath the diaphragm, situated more mesially than the collection of pus. The abscess cavity was packed.
>
> The subphrenic space itself was lightly sealed off by adhesions between the spleen and abscess wall on one side and the undersurface of the diaphragm on the other side. Thus there was no true subphrenic abscess.
>
> Postoperatively, the patient showed no improvement. The temperature continued to range from 102.4 to 106°F. despite blood transfusions and the administration of sulfathiazole. On the 2nd day the patient became confused and disoriented. She continued to run a septic downhill course and died 3 days postoperatively.
>
> *Autopsy* (12407). The relevant findings at the autopsy performed by Dr. L. Strauss, were reported as follows:
>
> The spleen is enlarged, weighing 380 gm. At its upper pole there are two large irregular defects, one on the anterior surface, the other on the posterior surface underneath the adherent diaphragm. In the vicinity of these defects, the capsule shows irregular, yellowish-gray discoloration, over the remainder of the organ it is smooth and of normal color — purplish gray. On section, a huge, multiloculated abscess is found, involving about half the spleen. It is lined by ragged, necrotic tissue and filled with blood clots. The lower half of the spleen is soft and shows abundant bright-red pulp and distinct follicles. The splenic artery shows no change.
>
> From the portal spaces thick, yellow pus exudes in many areas throughout the liver. The portal vein is thickened, and its lumen contains adherent membranous fibrinous material and frank pus. Pus also wells up from many of its intrahepatic branches. At the point of junction of the superior mesenteric and splenic veins and in the splenic vein, slightly adherent fibrinous thrombi are encountered.
>
> The right tube is thickened and hyperemic, and its fimbriated end is closed. In the cul-de-sac, irregular, raised yellow patches are seen on the serosa.
>
> The small intestine does not show noteworthy changes except for the lower part of the ileum, where numerous fibrous bands are found connecting various loops. There is grayish discoloration of the serosa, which is irregularly thickened over the mesentery. Small yellow patches are found on the mesentery near the insertion of the bowel. The branches of the superior mesenteric veins are not involved by the thrombotic process. The cecum is adherent to the ileum; the appendix has been removed.
>
> Anatomical diagnoses: purulent thrombophlebitis of the portal and splenic veins; left subphrenic and splenic abscess; chronic mesenteritis and localized peritonitis of the ileocecal region; chronic right salpingitis; and chronic peritonitis of the cul-de-sac.

Summary

Splenic abscess is an infrequent but not rare condition. Its diagnosis is not difficult when it is kept in mind. A patient who develops symptoms and signs of a lesion in the left upper abdomen and who has a recent history of even minor suppuration elsewhere should be explored and splenotomy or splenectomy performed.

A case of splenic abscess is reported that had its origin in a diffuse inflammatory process of the pelvic peritoneum. The abscess was accompanied by a pylephlebitis and a thrombophlebitis of the splenic vein that led to a fatal outcome, despite surgical intervention.

References

1. Elting, A. W., Abscess of spleen. *Ann. Surg.* **62**:182-192, 1915.
2. Inlow, W. DeP. Traumatic abscess of spleen. *Ann. Surg.* **85**:368-379, 1927.
3. Billings, A. E. Abscess of spleen. *Ann. Surg.* **88**:416-428, 1928.
4. Walker, I. J. Abscess of spleen. *New Eng. J. Med.* **203**:1025-1028, 1930.
5. Lemmon, W. T., and Paschal, G. W., Jr. Splenic abscess with drainage and recovery. *Am. J. Surg.* **56**:641-646, 1942.
6. Lenormant, C., and Sénèque, J. Les abcès de la rate. *J. de chir.* **21**: 685-698, 1923.
7. Kuttner, H. Quoted by Varachaud, R. P. E. *Les abcès de la rate et leur traitement.* Thèse pour le doctorat en médecine, Université de Bordeaux, 1934-35.
8. Caldarera, E. L'ascesso acuto della milza. Studio clinico e ricerche sperimentali. *Ann. ital. di chir.* **16**:953-994, 1937. Abstracted in *Surg. Gynec. & Obst. (Internat. Abstr. Surg.)* **67**: 265, 1938.
9. Fauntleroy, A. M. Report of case of splenic abscess. *J. A. M. A.* **56**: 260, 1911.
10. Cooke, W. T. Diverticulitis with unusua termination. *Lancet* **1**: 84, 1937.
11. Cutler, E. C. Abscess of spleen; report of case with recovery following operation. *J. A. M. A.* **75**:1712-1713, 1920.
12. Eliason, E. L. Splenic abscess. *Ann. Surg.* **97**:301, 1933.
13. Rabin, C. B., and Moolten, S. Pylephlebitis complicating gangrenous pulmonary abscess. *Arch. Path.* **16**:436-438, 1933.
14. May, M. A propos des abcès de la rate. *Mém. Acad. de chir* **63**:567-570 ,1937.

MEDICAL PROGRESS

SYPHILIS (Concluded)

G. Marshall Crawford, M.D.*

BOSTON

Clinical Problems

Syphilis in Blood Donors

A study of the method of handling blood donors found to have a positive or doubtful reaction for syphilis has been made by Frye, Keller and Kampmeier.[36] A geographically representative group of 603 hospitals replied to a questionnaire sent out by these authors. Of these institutions, 6.5 per cent were not testing blood donors for syphilis, small hospitals predominating. Among the hospitals testing donors, 12.5 per cent had no definite system for notifying these donors when they were found to have a positive or doubtful reaction for syphilis. Of all the hospitals, 16.2 per cent either did not examine donors for syphilis or did not notify them when the serologic test was positive. These findings indicate the need in many hospitals of more definite plans whereby the donors will be given blood tests and will be notified concerning the results. The present situation seems most deplorable. It could be construed as a grave reflection on hospital authorities, especially in view of the intense campaign to control syphilis. Financial considerations are, of course, sometimes strong deterrents, but surely it should not be too much to expect even the smallest institutions to send blood specimens to their state laboratories. One could even conceive of a malpractice suit arising on the basis of negligence should transfusion syphilis occur, or should an untested donor develop crippling lesions within a reasonable period of time.

False-Positive Serologic Reactions following Smallpox Vaccination

A reference to the phenomenon of false-positive serologic reactions following smallpox vaccination was given in a previous progress report on syphilis in this journal.[37] It seems of sufficient importance to warrant mentioning confirmatory data. Lubitz[38] observed 13 of 100 patients who exhibited positive serologic reactions for syphilis following a primary take with smallpox vaccination. All these cases had been serologically negative within a few months previously. Infectious mononucleosis was ruled out by a heterophile antibody test in the serums from 10 cases. The Kahn verification test gave no conclusive evidence that these were false-positive reactions. Twelve of the patients could be followed, and their serums gradually became negative. The author states that a positive serologic test may be found as late as the fifth month following vaccination.

Syphilitic Spondylitis

A report by Freedman and Meschan[39] seems of interest because syphilitic spondylitis, although not common, can be so easily confused with other conditions. The authors point out the difference between syphilitic spondylitis and Charcot's spine. There seems to be a marked predilection for involvement of the cervical vertebras in syphilitic spondylitis, possibly because of more likely exposure to slight trauma and pressure. The condition may occur in congenital syphilis or during the second or third stage of acquired syphilis. There is localized pain, which may be more marked at night, stiffness and tenderness to palpation. The normal lordosis of the spinal column is offset. The head is held stiff and motion is avoided. Coexisting osseous lesions are common. To substantiate a diagnosis, active syphilis should be demonstrable and there should be rapid improvement under antisyphilitic treatment. Tuberculosis of the spine may be confusing, and the two conditions may coexist. In the majority of cases the vertebras become surrounded by more or less spur formation, imitating roentgenographically the appearance of a nonsyphilitic inflammatory spondylitis.

Neurosyphilis

The interpretation of spinal-fluid reports is often a source of concern to general practitioners, and a discussion of this subject by Rose[40] is instructive. The point is made that cerebrospinal-fluid examination is essential in establishing the diagnosis of neurosyphilis, as well as in establishing the base line for future guidance. The initial findings do not, of course, indicate the prognosis. The several spinal-fluid findings in the various types of neurosyphilis are reviewed, and the significance of component parts of the reports is explained. Rose believes that the reversal of a positive spinal-fluid reaction to negative with a year or less of treatment is strong evidence against a diagnosis of general paresis, irrespective of clinical symptoms. Repeated examinations of the spinal fluid are considered essential for guidance and adequate therapy. This author states that the cell

*Instructor in dermatology, Harvard Medical School; assistant dermatologist, Massachusetts General Hospital.

count and the level of total protein are of much greater importance regarding prognosis and therapy than is the Wassermann test or the gold-sol curve. It is postulated that a spinal fluid that remains strongly positive in all elements for a year or more after the institution of therapy shows that some other form of treatment should be considered. Most syphilotherapists are somewhat less conservative in this respect. In asymptomatic neurosyphilis six months of routine therapy with trivalent arsenic and bismuth is usually considered sufficient trial, complementary methods of therapy being instituted at the end of this time if the spinal fluid is not improved. In the various forms of symptomatic neurosyphilis it may be necessary to use more drastic forms of therapy within a few weeks or months if symptomatic progression is not retarded.

In view of widespread, and in some instances alarming, epidemics of anterior poliomyelitis within the last year, an article by Barker[41] seems timely. A case exhibiting an acute syphilitic anterior poliomyelopathic syndrome was reported. Although this picture is seldom seen, syphilis has been reported in a small number of cases as responsible for the origin of the syndrome of anterior poliomyelitis. Barker's patient was thirty-nine years old, and a diagnosis of acute anterior poliomyelitis was made on admission to the hospital. Laboratory tests showed strongly positive Wassermann reactions of the blood and cerebrospinal fluid. The case was observed in March, which is an untimely month for acute anterior poliomyelitis. There were absence of pain and a peculiar distribution of paralysis, inability to swallow existing in conjunction with weakness of both legs. Five days after admission the patient became unable to void urine. Under intensive antisyphilitic therapy with bismuth, arsenic and potassium iodide, improvement was rapid, and within two months the symptoms had almost disappeared. The lesson in this situation seems obvious. Intensive antisyphilitic treatment under such circumstances may prevent changes in the spinal cord that are not already irreparable from becoming so, by the restitution of better circulatory conditions in the cord through regression of the vascular syphilitic progress.

Trauma has long been implicated as a contributory factor in the development of many lesions of syphilis. Ample evidence in favor of this belief has been found from time to time. Merritt and Solomon[42] present further substantiation of the role of trauma in the production or exaggeration of symptoms in the various types of neurosyphilis. It is stated that a causal relation between head trauma and the development of paretic symptoms may be established within six weeks of the trauma and perhaps as long as two to three years after it. The relation of trauma to syphilitic arthropathies affords less opportunity for divergence. It is generally accepted today that Charcot's joints develop as a result of lessened sensitivity in the joints that allows repeated minor trauma to occur without protection by the muscles or the tendons. There is less evidence of the effect of injury in other types of neurosyphilis. The one proved fact is that neurosyphilis is due to invasion of the nervous system by a spirochete. The deleterious effect of trauma on the pathologic process of neurosyphilis can only be deduced. There is divergence of opinion about the severity of trauma necessary and the time interval that must elapse between the injury and the appearance of symptoms.

In a review of tabetic arthropathies, Steindler, Williams and Puig-Guri[43] analyze the findings in 134 cases in which there were two hundred and fourteen Charcot's joints. A definite picture of tabes was present in only 57 of these cases. The age limits were from seventeen to eighty-two years. Of these patients 97 per cent were men. Various injuries preceded the onset of arthropathy in 59 cases (44 per cent). The time interval between the acquisition of syphilis and the onset of joint symptoms varied between five and ten years. These cases were analyzed from numerous aspects for statistical purposes. There were only 5 cases in which the joints of the upper extremities were involved. The knee was the most frequently affected joint (51 per cent of all joints, or 64 per cent of the 134 patients). Ten cases became complicated with pyogenic infection through ulcers and local sores, and all but 2 of these came to amputation. These authors believe that trauma is never the cause of syphilitic arthropathy but is undoubtedly of contributing importance in its development. It is pointed out that normal fractures may occur in a tabetic patient or in one suffering from syringomyelia, and may be produced by a perfectly adequate and plausible traumatic event.

Congenital Syphilis

An interesting point of differential diagnosis has been discussed by Henderson.[44] Over a five-year period he observed 53 infants with erythroblastosis. Ten were stillborn, 24 died, and 19 recovered. Autopsies were performed on all 34 fatal cases. Henderson points out that the two severest forms of erythroblastosis, hydrops fetalis and hepatic cirrhosis, occur in connection with intrauterine death and are usually mistaken for congenital syphilis. A large, pale placenta occurs in both these diseases. Uncertainty will seldom arise if certain points are considered in all doubtful cases. The occurrence of a proved case in an older sibling makes the diagnosis almost certain. Congenital syphilis becomes progressively less severe in each succeeding pregnancy; in erythroblastosis the trend is opposite. The frequency and degree of prematurity are much higher in syphilitic infants than in those with erythroblastosis. The gross appearance of the placenta may be strikingly similar, but syphilitic placentas usually show areas of infarction. Osseous manifestations are absent in erythroblastosis. The

demonstration of *Treponema pallidum* in the tissues of the fetus, cord or placenta dispels doubt; it can often be found by immediate scrapings of the intima of the umbilical vein. Microscopical examination of tissue is, of course, of great assistance, but occasions some delay.

For practical purposes it is generally considered that one can disregard the possibility of cardiovascular syphilis in congenital cases. An exhaustive review of this problem has been published by Hinrichsen.[45] The literature has been painstakingly searched, and reported cases are discussed. Hinrichsen found reports of various types of vascular syphilis, with the exception of valvular heart lesions. Although congenital syphilitic aortitis, with or without aneurysm, has been reported, this author found no case on record with syphilitic valvular lesions of the heart. Congenital syphilitic myocarditis of interstitial and nodular types has been described but its incidence is uncertain. Autopsies on stillborn or early post-natal fatalities are almost the only cases recorded. The role of syphilis in the production of congenital malformations of the heart has not been determined. Congenital syphilis as a cause of hemorrhagic disease of the newborn is also mentioned in this paper.

A study of the possible effect of bismuth on the growth of children has been made by Russin, Stadler and Jeans.[46] It is reasonable to assume that there may be interference with growth, since the abnormal changes observed roentgenographically after the administration of bismuth appear at the sites of provisional ossification of growing long bones. These authors followed 10 children under treatment for congenital syphilis for periods as long as ten years. Their actual heights were compared periodically, with the predicted height, and the average difference in most cases was practically zero. The conclusion was drawn that, although the roentgenographic changes observed represent abnormalities of bone growth, the prolonged administration of bismuth does not interfere with the rate of linear growth.

The intramuscular method of administration of Mapharsen has been utilized by Astrachan and Cornell[47] in congenital syphilis. Sixty-eight patients with various stages of congenital syphilis, as well as 19 with latent acquired syphilis, were treated. Most of those with early congenital syphilis were treated by the intramuscular route, and the rest intravenously. The majority of the patients tolerated well the intramuscular injections of Mapharsen and showed no untoward reactions. Clinical and serologic results were satisfactory. These authors believe that the concurrent administration of Mapharsen and bismuth is often valuable in late congenital syphilis. They think that 0.75 mg. per kilogram of body weight should be the maximum dosage for any patient with congenital syphilis.

Levin, Hoffman, Koransky, Richter and Gumbiner[48] have applied the principles of massive therapy to the treatment of syphilis in infants and children. Thirty-two cases of congenital syphilis and 4 in children with the acquired disease were given the five-day treatment with Mapharsen. The authors properly stress the importance of adequate pediatric care during this procedure. No serious toxic reactions or deaths occurred. The 4 cases of acquired infection promptly became seronegative; the congenital cases were notably inferior in response when compared to those of early acquired syphilis in adults. This led the authors to believe that congenital syphilis produces widespread changes more resistant to treatment than acquired syphilis. In considering this, one would hardly expect anything else unless only selected cases of early congenital syphilis in children (from birth to the age of six months) were treated. Otherwise, they would not be comparable to those of early syphilis in adults.

Therapy

Penicillin

At the seventy-second annual meeting of the American Public Health Association, Mahoney, Arnold and Harris[49] reported favorable results in the treatment of 4 cases of early syphilis exclusively with penicillin. Each received 1,200,000 units of the drug in eight days. Dark-field examinations became negative about seven hours after the treatment was begun. Lesions were healed within two weeks. Serologic tests for syphilis became negative within thirty days. At the time of this writing, these patients had remained negative for approximately eight months. This is indeed a most startling report, and certainly one may hope for a great advance with the use of such a remarkable drug. As often before mentioned, however, caution must be exerted in predicting any results with new treatment for syphilis. It will take several years to determine whether penicillin is generally indicated in this disease. It may take ten or more years to tell whether its results are lasting. Dr. Mahoney himself, in reading this paper, urged caution in interpreting results. It is to be remembered that penicillin is not available for general use and that only a limited amount can be spared for the study of syphilis at this time.

Other Drugs

Trisodarsen. A résumé of eight years' experience with Trisodarsen has been published by Beerman, Pariser and Gordon.[50] The results of treatment of 550 patients in various stages of syphilis were analyzed. Forty-four per cent had reactions, although the majority of them were mild. Infectious and serologic relapses occurred in 10 per cent of 177 patients with early syphilis. This compared favorably with the Co-operative Clinical Group statistics of 10.1 per cent. In all other respects the results were comparable to those expected with drugs in common use, but the authors state that their patients have not been observed long enough to

evaluate definitely the probabilities of cure of syphilis from this drug, although the trend appears to be favorable. The main drawback seems to be an apparent tendency of this compound to induce dermatitis.

Phenarsine hydrochloride. Two preliminary reports have appeared on the treatment of syphilis with phenarsine hydrochloride. Long[51] subjected 96 patients to treatment with this drug. It was administered in a standardized manner, with bismuth in alternate series. Open lesions were rapidly sterilized, and healed satisfactorily. There was no case of relapse. The rapidity of serologic reversal was on the whole satisfactory. There was a low incidence of abnormal spinal fluids among the patients with early syphilis. The drug was well tolerated in late syphilis and the response was good. Guy, Goldmann and Gannon[52] have also used phenarsine hydrochloride. These investigators worked out data on toxicity and cures in rats according to standard procedures. The results did not differ materially from those obtained with Mapharsen. Two hundred and thirty-three patients were subsequently treated by a standard continuous program with alternate courses of bismuth. The results were comparable to those of Long.[51] Guy, Goldmann and Gannon also believe that phenarsine hydrochloride compares favorably with other drugs that are now in general use and think that it may prove more stable. Forty milligrams of the drug was administered daily for twenty-five successive days to a woman patient. The secondary cutaneous lesions disappeared at the end of ten days, and the patient tolerated the drug without any ill effects.

Clorarsen. Clorarsen has been used in the treatment of syphilis by Kampmeier and Henning.[53] Two hundred and fifty patients with early syphilis were treated, with satisfactory response in all respects. A standard continuous program, with alternating courses of bismuth, was employed. A single therapeutic dose produced dark-field negativity within twenty-four hours in 42 of the 45 infectious cases. No serious untoward reactions were encountered. The drug was used often without reaction in patients who had had difficulty with other arsenical preparations. The experimental use of clorarsen seems to indicate that it is effective in acute syphilis, is attended by few reactions, and may be used as an alternate drug in patients who have had reactions to other arsenical drugs.

Bismarsen. A review of fourteen years' experience with Bismarsen has been published by Beerman, Shaffer and Livingood.[54] Eight hundred and twenty-three syphilitic patients were treated with the drug during this time. All stages of the disease were included. The authors state that Bismarsen is a relatively nontoxic drug. It was frequently used in treating patients who had had unfavorable reactions to other arsenicals. This experience seems to be at variance with that of other syphilotherapists. Perhaps more statistical study would prove these authors correct, but it seems to be a common impression that patients intolerant to intravenous arsenotherapy are more likely to develop reactions when Bismarsen is administered. Beerman, Shaffer and Livingood found that the lesions of early syphilis healed more slowly under Bismarsen therapy than under other arsenicals and that its spirillicidal action was slower. They consider it a safe and effective drug for the treatment of cardiovascular syphilis. The action of Bismarsen was found to be too slow for use against interstitial keratitis. The authors believe that it is not the drug of choice for neurosyphilis, but that for persons for whom fever therapy and other forms of chemotherapy are contraindicated it is a useful substitute. One would be justified in thinking that Bismarsen is not the drug of choice but a secondary measure primarily suitable for those in whom intravenous therapy is not feasible.

Bismuth. Two additional reports have appeared concerning the tempering effect of bismuth on therapeutic malaria. This phenomenon was mentioned in a previous progress report.[55] Thio-Bismol is the preparation employed. It has proved extremely useful in the hands of Whelen and Shute.[56] These authors found that an injection of 0.2 gm. of Thio-Bismol was effective in stopping malarial paroxysms for forty-eight hours, the drug having a selective action on alternate cycles of benign tertian malaria during the developed stage. If administered during the incubation period the drug did not appear to have any effect on the time of onset or type of fever. Proper use of this procedure can extend the range of cases that can be treated and may be of great assistance in certain emergencies. Young, McLendon and Smarr[57] have had similar experience with Thio-Bismol. These authors found that the inhibitory effect against *Plasmodium vivax* was most marked when the parasites were half grown — that is, sixteen to twenty-four hours after the last paroxysm. Older or younger parasites might not be affected at all. Other species, such as *P. malariae* and *P. falciparum*, were uninfluenced by Thio-Bismol. For the termination of *P. vivax* infections, these authors found that one injection of the drug, given on the day quinine was started, usually acted more quickly than did quinine alone by preventing a paroxysm the following day.

The importance of oral hygiene during bismuth therapy has long been known. It is a prophylactic measure that serves to ward off oral complications that may be most disturbing. Dean[58] has published a report that serves to emphasize this fact. A dark line on the gums, bleeding of the gums, excessive salivation, a bad odor of the breath, puffing and swelling of the gum tissue and an occasional loosening of the teeth were found to be remarkably improved by mouth care in the hands of dental clinics. Test cases were developed by giving general dental

care to half the lower jaw of patients showing symptoms of bismuth stomatitis. The other half of the lower jaw was not treated. There is much that the patient can do at home in the way of general mouth hygiene, gum massage and so forth. Analysis of the black deposit at the gingival margins indicates that it is probably bismuth sulfide. Dean believes that it is not necessary to interrupt or discontinue the use of bismuth treatment if adequate dental service is given before or during the periods of injection. These are well-known facts, but repetition seems worth while at this time. Dean's procedure in treating only half of one jaw provided an unquestionably satisfactory control.

Intensive Therapy

Although complications were frequent and comparatively serious with earlier attempts at massive therapy, gradual improvement and modifications of technic have slowly created a more favorable situation. Eagle and Hogan[50] have approached this problem from the experimental standpoint through a study of toxicity and excretion of Mapharsen in rabbits. Various programs of multiple injections and intravenous-drip administration were used. It was found that the total amount of Mapharsen tolerated by the animals is apparently without limit, with suitable prolongation of the treatment period. It was found possible by increasing the frequency of injections to increase significantly the amount of Mapharsen that can be administered with safety within a given period. In a continuation of this study, Eagle and Hogan[50] worked out the therapeutic efficiency and margin of safety of Mapharsen in the treatment of rabbit syphilis. The curative dose of the drug was largely unaffected by the method of administration. Multiple-syringe technics were more effective than intravenous drip procedures. The margin of safety between the toxic and therapeutic dose could be increased by appropriate prolongation of the treatment period. An appreciable condensation of treatment beyond that permitted by triweekly, daily or multiple daily injections can be accomplished only at the cost of safety by an arbitrary decrease in the total number of injections. In a third article of this series Eagle and Hogan[51] discuss the clinical implication of their experimental work. An optimal treatment schedule was worked out for the management of early syphilis in the human being. This was based on the experimental animal data and published reports on the treatment of human syphilis. Without exception, and despite the reservations that must be applied to a chemotherapeutic index based on a toxicity study in animals, the observed incidence of serious toxic reactions and death has varied inversely with the calculated margin of safety. A triweekly schedule of Mapharsen injections was worked out as having a satisfactory margin of safety. Dosage was calculated on a body-weight basis (1 mg. per kilogram), and treatment was continued for a period of four to twelve weeks. The four-week schedule proved inadequate, as was predicted. The other schedules were continued. Approximately half the patients received weekly injections of bismuth to determine to what extent that drug would modify the end results. More than eighty marine hospital and university, municipal and state health-department clinics are now co-operating in this study. At the time of Eagle's report 2500 patients had been treated. The detailed analysis of the initial results will be described in a later paper. Another observer, Shaffer[52] has evaluated the published reports on massive therapy from a clinical standpoint. He believes that intensive methods of treatment should still be considered experimental, and warns against the attempted use of such procedures by physicians without extensive experience. As further information is accumulated, it is expected that the experience of well-controlled work will permit the establishment of a definite procedure to be recommended in the not too distant future for use in private practice. Intensive therapy in various types of latent and late syphilis is far behind that of early syphilis. I cannot agree too heartily with Shaffer's opinions.

Combined Fever and Chemotherapy

In last year's progress report[53] attention was called to promising results with the use of a single artificial-fever treatment combined with chemotherapy in one intensive session for early syphilis. A subsequent report by the same authors, Thomas, Wexler, Shur, and Goldring,[54] described a serious renal complication. Forty-eight patients were treated under a two-day schedule consisting of two intravenous injections of Mapharsen on the first day, followed on the second day by two more with seven hours of artificially induced fever. Four of these patients developed acute nephrosis and 4 others severe albuminuria, together with azotemia of brief duration. All eight recovered from the acute episode. The cases were described in detail and were doubtless extremely alarming. The authors believe that the complication in these patients was an acute nephrosis induced by the combination of arsenic and prolonged use of artificial fever. This emphasizes the caution required in evaluating the safety of heroic experimental treatment of syphilis.

Reactions to Therapy

Hepatitis

Jaundice occurring during the course of antisyphilitic therapy has been a source of concern to a great many observers. Two series of cases reported within the last year seem of interest. Kulchar and Reynolds[55] have published a survey of 144 cases. They postulate the usual causes of jaundice as intercurrent infection, arsenic intoxication or hepatorecurrence. Their cases occurred among 1032

syphilitic prison inmates, the incidence being rather high (13.9 per cent). Kulchar and Reynolds were studying hepatitis primarily from the standpoint whether bismuth was the etiologic agent, but only 4 of their cases had been treated with bismuth alone; 83 followed within four to eight weeks after the termination of arsenical therapy, and 56 within eight or more weeks. Treatment was subsequently resumed in 107 patients, 9 of whom developed a second attack of jaundice. In 4 of these cases the attack followed bismuth, and in 5 arsenic. These authors believe that previous arsenical therapy, diet, alcohol and intercurrent infection may predispose the patient to liver damage from the administration of bismuth. In other words, a summation effect of several factors, all individually unable to produce hepatitis, is proposed. Bismuth is thus placed in the role of precipitating the attack of jaundice. In the end, however, Kulchar and Reynolds favored the preceding arsenotherapy as of considerable importance. Syphilotherapists in general might question the frequency of a precipitating effect of bismuth in jaundice. It cannot be denied, however, that bismuth may create some liver damage or that it could be the last straw, so to speak, in the face of pre-existing liver damage. Ottenberg and Spiegel[66] have written on the present status of nonspecific jaundice due to infectious and chemical agents. They think that disease of the hepatic parenchyma may be due directly or indirectly to infection or to chemical agents. In their experience, clinical features of single cases are of little help in determining etiology, and tests of hepatic function have from the etiologic standpoint been largely fruitless. It is pointed out that syphilis is one of the infectious diseases that can cause hepatitis. It is stated that half the fatal cases of congenital syphilis show liver involvement, that some evidence of syphilis of the liver is found in approximately 1 per cent of secondary syphilis, and that about 10 per cent of the severer cases progress to acute yellow atrophy. Arsenic is said to belong to the group of drugs considered hepatotoxic, and the mechanism is considered to be one of idiosyncrasy, hypersusceptibility or allergic sensitivity. Since syphilis itself can damage the liver, and its most powerful antidote is hepatotoxic, the disease together with arsenotherapy could certainly be expected to produce liver damage from time to time. Ottenberg and Spiegel found reports in the literature quoting the incidence of so-called "arsenical jaundice in syphilotherapy" as approximately 1 per cent or less. Comparing these figures with those of Kulchar and Reynolds,[65] one would suspect that the prison inmates treated by the latter may have been strongly influenced by intercurrent infection of epidemic proportions. Ottenberg and Spiegel believe that bismuth is possibly a hepatotoxic drug, but that it is far weaker in that respect than is arsenic.

Kopp and Solomon[67] have studied the effect of prolonged tryparsamide therapy on liver function. Their material consisted of 66 patients with syphilis of the central nervous system. In most cases the drug was given weekly in 3-gm. doses. One patient had received the amazing total of five hundred and thirty-nine injections of tryparsamide. A number of them had also been treated with bismuth, trivalent arsenical therapy, or mercury or some form of fever therapy or both. Normal liver function was found in 16 of the patients. The remaining 50 revealed abnormal findings in one or more tests. Studies included the bromsulfalein test, phospholipids, fibrinogen, cholesterol esters, hippuric-acid excretion, icteric index, bilirubin, the van den Bergh reaction and the cephalin flocculation test. Abnormalities were slight enough to lead these authors to conclude that tryparsamide causes relatively little liver damage even when given over a long period of time (as long as eighteen years) and combined with fever therapy. Jaundice occurring during therapy under all these circumstances is considered by Kopp and Solomon to cause no important damage to the liver and is not held to be a contraindication to the further use of tryparsamide. It is sometimes surprising how much the human organism can tolerate.

Arsenical Reactions

Robinson[68] discusses reactions to arsphenamine from the standpoint of their effect on syphilis as well as on the patient. Severe exfoliative dermatitis and hepatitis have been thought at times to have a favorable influence on the course of the disease. Robinson reviews the cases of 381 patients who recovered from these complications and were followed for three months to twenty-one years. He found no evidence that severe treatment reactions of any sort play a part in the cure or amelioration of syphilis. He does not believe that arsenotherapy should be withheld from the patient who has seborrheic, atopic, contact or other itching dermatoses. This sounds a little dogmatic. It has been a matter of common observation that severe and extensive dermatoses may indeed be exacerbated by arsenotherapy and may progress to universal exfoliative dermatitis. Robinson outlines measures to avoid reactions of all types, the management of reactions and the factors to be considered before resumption of therapy, if it is to be resumed. He emphasized the well-known fact that exfoliative dermatitis is a positive contraindication to further arsenotherapy.

A method of circumventing reaction to arsenical drugs is described by Beerman, Pariser and Wammock.[69] The many reports in recent years regarding the possible value of vitamin C in the prevention of reactions led these investigators to study various solvents containing vitamin C for use as diluents in administering arsenic intravenously. Methylglucamine ascorbate was found to be the

most useful solvent. A 7 per cent solution of sucrose was utilized as the diluent. One hundred and fourteen patients who had exhibited some sort of reaction, usually mild, that on occasion necessitated the discontinuance of arsenical therapy were treated. This mixture seemed to have a beneficial effect on about half the patients who had had nausea and vomiting or nitritoid crises. One hundred milligrams of the ascorbic acid derivative was found to be the optimal dose.

Stephenson, Chambers and Anderson[70] report the annual statistics of the United States Navy on the toxic effects of arsenical compounds. One fatality from Mapharsen (from cerebral hemorrhage) is included in the current report. Total reactions from Mapharsen averaged one third as many as from neoarsphenamine. Dermatitis comprised 45 per cent of the total reactions, as compared with 55 per cent in the preceding year. The type of lesion was erythematous in 3 cases, exfoliative in 3 and macular, maculopapular, morbilliform and scarlatiniform in 1 each. Six cases of these dermatoses were mild, and 4 were severe.

Bismuth Eruptions

This subject is interesting, and it is doubted whether the average physician realizes either the frequency or the variety of dermatoses that can occur during bismuth therapy. Noojin and Callaway[71] have reported on the subject of bismuth eruptions in antisyphilitic therapy. Acute eruptions are listed as erythematous, exfoliative, scarlatiniform, urticarial, purpuric and multiform and as similar to those of herpes zoster. Chronic bismuth eruptions may assume a pityriasis rosea type, lichen planus type, lichen simplex chronicus type (neurodermite), a fixed eruption or a generalized chronic eczematoid dermatitis. It should be emphasized that none of these are commonly observed. For that reason their occurrence may be confusing to those not treating large numbers of patients with syphilis.

Summary

Although this year's report seems of considerable interest in its totality, a few items will bear reemphasis.

Perhaps one of the most remarkable matters is the failure to follow up blood donors who have been found to have a positive serologic test for syphilis. It seems imperative that some means be found for all hospitals to do better with the problem. Other reports concerning the public-health aspect of syphilis control that are of considerable interest include good results in the operation of the Connecticut law governing premarital blood tests, the consultation program for local physicians provided by the State of New York, the so-called "facilitation process" employed in British Columbia to get at the source of venereal disease and an encouraging reduction of the incidence of syphilis in the Army.

Syphilis in industry has received considerable mention in the recent literature. An outstanding example of the effectiveness of syphilis control in this field is the plan in use at the Remington Arms Company.

A most hopeful advance in the field of therapy is the use of penicillin for the treatment of syphilis. It is naturally too soon to go farther than to mention the possible successful treatment with this powerful drug. Considerable work is being continued in the field of intensive therapy, with various modifications in methods and encouraging results. The matter of increased reinfections following massive therapy is becoming of some importance.

The experimental use of arsenical drugs by intramuscular and oral administration in the treatment of syphilis seems hopeful. Should these procedures prove satisfactory, they would greatly enhance the ease of administration and the co-operation of patients.

References

36. Frye, W. W., Keller, A. E., and Kampmeier, R. H. Hospital and syphilis problem in prospective blood donors. *J. A. M. A.* **121**: 182-186, 1943.
37. Lane, C. G., and Crawford, G. M. Syphilis. *New Eng. J. Med.* **226**: 97-104, 1942.
38. Lubitz, J. M. Serologic reactions following smallpox vaccinations. *Am. J. Clin. Path.* **13**:139-143, 1943.
39. Freedman, E., and Meschan, I. Syphilitic spondylitis. *Am. J. Roentgenol.* **49**:756-765, 1943.
40. Rose, A. S. Interpretations of spinal fluid in neurosyphilis. *Dis. Nerv. System* **3**:280-282, 1942.
41. Barker, L. F. Acute syphilitic anterior poliomyelopathic syndrome: report of case. *Arch. Neurol. & Psychiat.* **49**:118, 1943.
42. Merritt, H. H., and Solomon, H. C. Symposium on problems relating to law and surgery: relation of trauma to syphilis of nervous system. *Ann. Surg.* **117**:623-631, 1943.
43. Steindler, A., Williams, L. A., and Puig-Guri, J. Tabetic arthropathies. *Urol. & Cutan. Rev.* **46**:633-649, 1942.
44. Henderson, J. L. Erythroblastosis or congenital syphilis? Observations on erythroblastosis and its differential diagnosis from congenital syphilis. *J. Obst. & Gynaec. Brit. Emp.* **49**: 499-511, 1942.
45. Hinrichsen, J. Cardiovascular involvement in congenital syphilis: review of literature. *Am. J. Syph., Gonor. & Ven. Dis.* **27**: 319-375, 1943.
46. Russin, L. A., Stadler, H. E., and Jeans, P. C. Bismuth lines of long bones in relation to linear growth. *J. Pediat.* **21**: 211-213, 1942.
47. Astrachan, G. D., and Cornell, V. Mapharsen in treatment of congenital syphilis, with especial consideration of intramuscular method of administration. *J. A. M. A.* **121**: 746-752, 1943.
48. Levin, I. M., Hoffman, S. J., Koransky, D. S., Richter, I. B., and Gumbiner, B. Congenital and acquired syphilis in infants and children: treatment with massive doses of arsenic intravenously. *J. A. M. A.* **120**:1373-1375, 1942.
49. Mahoney, J. F., Arnold, R. C., and Harris, A. Penicillin treatment of early syphilis: preliminary report. *Ven. Dis. Inform.* **24**:355-357, 1943.
50. Beerman, H., Pariser, H., and Gordon, J. H. Further observations on trisodarsen for treatment of syphilis: résumé of eight years' experience. *Am. J. Syph., Gonor. & Ven. Dis.* **26**:670-680, 1942.
51. Long, W. E. Treatment of syphilis with phenarsine hydrochloride: preliminary report. *Arch. Dermat. & Syph.* **47**:226-234, 1943.
52. Guy, W. H., Goldmann, B. A., and Gannon, G. P. Phenarsine hydrochloride in treatment of syphilis: preliminary report. *Arch. Dermat. & Syph.* **47**:235-238, 1943.
53. Kampmeier, R. H., and Henning, H. B. Treatment of syphilis with clorarsen. *Am. J. Syph., Gonor. & Ven. Dis.* **27**:208-217, 1943.
54. Beerman, H., Shaffer, B., and Livingood, C. S. Bismarsen (bismuth arsphenamine sulfonate) for treatment of syphilis: review of fourteen years' experience. *J. A. M. A.* **120**: 333-338, 1942.
55. Lane, C. G., and Crawford, G. M. Syphilis. *New Eng. J. Med.* **224**: 110-116, 1941.
56. Whelen, M., and Shute, P. G. Thio-Bismol in therapeutic malaria. *J. Trop. Med.* **46**:1-5, 1943.
57. Young, M. D., McLendon, S. B., and Smarr, R. G. Selective action of thiobismol on induced malaria. *J. A. M. A.* **122**:492-494, 1943.

58. Dean, M. R. Oral manifestations of bismuth therapy in treatment of syphilis. *J. Am. Dent. A.* **30**:651-657, 1943.

59. Eagle, H., and Hogan, R. B. Experimental evaluation of intensive methods for treatment of early syphilis. I. Toxicity and excretion. *Ven. Dis. Inform.* **24**:33-44, 1943.

60. *Idem.* Experimental evaluation of intensive methods for treatment of early syphilis. II. Therapeutic efficacy and margin of safety. *Ven. Dis. Inform.* **24**:69-79, 1943.

61. *Idem.* Experimental evaluation of intensive methods for treatment of early syphilis. III. Clinical implications. *Ven. Dis. Inform.* **24**:159, 1943.

62. Shaffer, L. W. Present status of intensive arsenotherapy of early syphilis. *Ven. Dis. Inform.* **24**:108-113, 1943.

63. Lane, C. G., and Crawford, G. M. Syphilis. *New Eng. J. Med.* **228**: 15-24, 1943.

64. Thomas, E. W., Wexler, G., Shur, M., and Goldring, W. Acute nephrosis complicating two day arsenic and fever therapy for early syphilis. *J. A. M. A.* **122**:807-809, 1943.

65. Kulchar, G. V., and Reynolds, W. J. Bismuth hepatitis: survey of one hundred and twenty-one cases. *J. A. M. A.* **120**:343-346, 1942.

66. Ottenberg, R., and Spiegel, R. Present status of non-obstructive jaundice due to infectious and chemical agents: causative agents, pathogenesis inter-relationships, clinical characteristics. *Medicine* **22**: 27-71, 1943.

67. Kopp, I., and Solomon, H. C. Effect of prolonged tryparsamide therapy upon liver function. *Am. J. Syph., Gonor. & Ven. Dis.* **27**:445-459, 1943.

68. Robinson, H. M. Resumption of antisyphilitic therapy following postarsphenamine reaction. *Pennsylvania M. J.* **46**:667-676, 1943.

69. Beerman, H., Pariser, H., and Wammock, V. S. Methyl glucamine ascorbate (ascorbic acid derivative) as solvent for arsenical drugs. *Am. J. Syph., Gonor. & Ven. Dis.* **27**:58-62, 1943.

70. Stephenson, C. S., Chambers, W. M., and Anderson, L. T. Toxic effects of arsenical compounds as administered in United States Navy in 1941 with special reference to arsenical dermatitis. *U. S. Nav. M. Bull.* **40**:1015-1020, 1942.

71. Noojin, R. O., and Callaway, J. L. Bismuth eruptions in antisyphilitic therapy. *Urol. & Cutan. Rev.* **46**:458-461, 1942.

230
44

CASE RECORDS OF THE MASSACHUSETTS GENERAL HOSPITAL

Weekly Clinicopathological Exercises

FOUNDED BY RICHARD C. CABOT
TRACY B. MALLORY, M.D., *Editor**
BENJAMIN CASTLEMAN, M.D., *Acting Editor*
EDITH E. PARRIS, *Assistant Editor*

CASE 30051

PRESENTATION OF CASE

An eighteen-year-old youth entered the hospital because of high blood pressure.

The patient was in excellent health until about seven months before admission, at which time he noticed the onset of occasional headaches. He had cold feet and legs at night, accompanied by hot flashes over the upper half of the body. Three months prior to entry he developed persistent nocturia, twice a night. There were one or two short episodes of dysuria, but no polyuria, pyuria, hematuria or incontinence. For years he had drunk two quarts of water daily. He had no increased thirst. About one month before admission he developed a sharp, occipital pain, which was accompanied by a dull ache over his eyes and over the bridge of his nose. At first the pain came on in the morning on waking, was relieved by work and returned in the afternoon or evening. Lately it had become persistent and prevented him from sleeping. About three weeks before admission, while being examined for a job, he was told that he had high blood pressure. The headaches became quite severe. Two days before admission he woke with a right facial paralysis. He had a slight nosebleed and palpitation, with slight nonradiating precordial pain, blurring of vision and mental confusion. He was unable to recognize his father. He had no vertigo, convulsion, unconsciousness, nausea, vomiting, fever, chills or anginal pains. He had lost 13 pounds of weight in two years.

The past history was entirely negative except for diphtheria as a child.

Physical examination showed a well-developed, well-nourished man in no distress. The lungs were clear. The left border of cardiac dullness was 8 cm. from the midsternal line in the fifth space. The sounds were forceful, regular, and of good quality. A loud third sound and a split second sound were heard at the base. The aortic second sound was greater than the pulmonic. There was complete right facial paralysis. No spasm, anesthesia or paresthesia was noted. The fundi showed rather marked generalized spasm. The disk margins were blurred, but there were no elevations; a few collections of cotton-wool exudate were seen, as well as two or three small bits of waxy exudate, in the left macula. Neurologic examination was otherwise negative except for bilaterally decreased tendon reflexes.

The blood pressure was 190 systolic, 140 diastolic. The temperature was 98.6°F., the pulse 80, and the respirations 20.

Examination of the blood showed a red-cell count of 5,700,000, with 14.5 gm. of hemoglobin. The white-cell count was 14,500, with 66 per cent neutrophils. The urine showed a specific gravity of 1.020. There were three or four red cells and one or two white cells in the sediment. The culture was negative. The stools were guaiac negative. A blood Hinton test was negative. The nonprotein nitrogen was 28 mg. per 100 cc.

X-ray examination of the chest showed slight enlargement of the left ventricle. An intravenous pyelogram was negative. A urine concentration test showed a specific gravity of 1.022. A phenolsulfonephthalein test revealed 40 per cent excretion in the first fifteen minutes, and 85 per cent in two hours. A lumbar puncture gave an initial pressure of 120 mm. of water; 10 cc. of clear colorless fluid was withdrawn, with a final pressure of 80 mm. There were 3 white cells per cubic millimeter, with a total protein of 82 mg. per 100 cc. The gold-sol test was 0011331000. Repeated blood-pressure determinations gave an average of 200 systolic, 140 diastolic, while lying down and sitting, and one of 150 systolic, 130 diastolic, while standing. The entire determination, however, was done in a single sitting over a period of only twenty-four minutes. A cold pressor test showed a systolic rise of 10 mm. and a diastolic rise of 10 mm. Blood-pressure determination after the administration of three doses of 3 gr. of sodium amytal within a period of three hours showed no definite change. An electrocardiogram revealed a normal rate of 85. The PR interval was 0.12 second; S_2 and S_3 were prominent; ST_2 and ST_3 were depressed, with increased T_2 and T_3.

The patient's condition remained essentially the same. There was a slow rise of blood pressure. On the sixth hospital day he developed a sore throat, with chilly sensations and increased sweating. The temperature rose to 102°F. Examination showed a beefy-red throat and bilaterally tender and enlarged posterior cervical lymph nodes. The white-cell count was 13,800, with 78 per cent neutrophils. A throat culture showed many beta-hemolytic streptococci. On the sixteenth hospital day he was given 2 gm. of sulfadiazine every two hours for two doses, followed by 1 gm. every four hours for six days. The throat culture became negative.

On the twenty-first hospital day he complained of discomfort in the right flank. There was some tenderness in the right costovertebral angle. The urine examination showed a specific gravity of 1.010 and a + test for albumin. The urine contained innumerable red cells, with occasional white cells and

*On leave of absence.

granular casts, which persisted for five days. A urine culture was negative. The temperature, pulse and respirations were normal. The blood pressure was 220 systolic, 165 diastolic.

An operation was performed on the twenty-sixth hospital day.

Differential Diagnosis

Dr. Harry A. Derow*: We are dealing with an eighteen-year-old boy with severe progressive arterial hypertension and without any history of antecedent renal or hypertensive disease. The onset of this condition apparently dated from about seven months prior to admission to this hospital. Because of the high diastolic pressure and the retinal picture of papilledema, cotton-wool spots and diffuse arteriolar spasm, we have to make a diagnosis of malignant hypertension. By making this diagnosis we are not referring to any specific pathologic process in the kidneys: that is, the term "malignant hypertension" is used as a clinical diagnosis.

Back in 1935, Dr. Mark Altschule and I[1, 2] pointed out that malignant hypertension is a syndrome that may occur with no evidence of existing hypertension, as the end stage of primary (essential) hypertension or as the end stage of a miscellaneous group of conditions characterized by secondary hypertension. We also pointed out that during the life of the patient exhibiting the syndrome of malignant hypertension it is usually difficult if not impossible to determine the nature of the underlying pathologic process, that the prognosis by and large of these patients is extremely poor and that the cases that offer some modicum of hope are those rare surgically amenable cases in which the syndrome has been precipitated by renal infarction or by the development of certain tumors of the adrenal gland (pheochromocytomas). Also, there are cases of malignant hypertension that despite the poor prognosis, develop spontaneous remissions, during which the fundi show amazing improvement. The blood pressure, however, remains the same and these patients may go on for a period of years only to succumb to the same rapidly progressive picture that they originally presented.

In this patient, what evidence do we have to indicate antecedent primary inflammatory renal disease? I should like to ask about the urine examinations. The number of examinations done is not given; also the presence or absence of albumin is not stated.

Dr. Benjamin Castleman: A + and a + + test were recorded in three out of nine examinations.

Dr. Derow: The fact that six of the nine urine specimens that were examined failed to show albumin makes me believe that we are probably not dealing with primary inflammatory renal disease upon which malignant hypertension has been superimposed.[3] I am unable to interpret the history of one or two short episodes of dysuria three months before entry, particularly since there was no pyuria, hematuria or incontinence. On the other hand, it is possible for patients with chronic inflammatory renal disease causing albuminuria to go along for many years without symptoms of any kind, with intact kidney function and with normal blood pressure, only to develop suddenly the picture that this patient presented. The normal intravenous pyelogram probably rules out polycystic kidneys or other congenital anomalies of the upper urinary tract. The possibility of an adrenal tumor cannot be eliminated by the finding of a normal pyelogram, and that of course is a possibility here. There is no mention made of scalloping of the ribs or of the blood-pressure values of the legs, so I think that we can probably eliminate coarctation of the aorta.

The possibility of a brain tumor is unlikely, because the patient presents the picture of scattered focal lesions in the cortex, midbrain, and pons, and it is difficult to visualize a brain tumor that would involve such dispersed areas. My explanation for the cerebral picture is that there were scattered necrotic vascular foci, which are often seen in patients with severe hypertension.

We are left with the diagnosis of the syndrome of malignant hypertension without any clear idea of the underlying renal lesion. There does not seem to be any impairment of renal or cardiac function, and the clinical picture is chiefly that of cerebral disease.

The clinical course of the patient is interesting. On the sixth day, he developed a streptococcal sore throat, and because of the persistence of a positive throat culture, he was given sulfadiazine. There is a question, of course, whether the throat culture would not have become negative in the course of time and whether sulfadiazine should have been given in the absence of active streptococcal infection. There is a difference of opinion on this matter. Not so long ago I had occasion to discuss with Dr. Maxwell Finland the matter of the administration of sulfadiazine to patients in the carrier state, and he is one who believes that sulfadiazine should not be given. The attending physicians probably wanted to eliminate the throat as a source of infection as quickly as possible prior to whatever operative procedure was going to be undertaken. During the course of the sulfadiazine therapy the patient developed discomfort in the right flank, tenderness in the right costovertebral angle, albuminuria, hematuria, pyuria and cylindruria. There is no mention made of the development of edema, nor of the urinary volume, during this period of what seems to be a renal complication following the administration of sulfadiazine. Is there any information in that regard?

Dr. Castleman: No.

Dr. Derow: The note does appear, however, that the diastolic pressure was elevated above the levels that were previously recorded. From the history

*Instructor in medicine, Harvard Medical School; associate visiting physician, Beth Israel Hospital, Boston.

and the findings we do not know whether this patient developed acute glomerulonephritis following the streptococcal sore throat occurring two weeks previously, without relation to the sulfadiazine ingestion. The possibility of infarction of the right kidney should also be considered, because such a pressure going up to much higher levels than the preexisting hypertension.

Dr. Paul D. White: Would the age of eighteen influence you at all in making a diagnosis?

Dr. Derow: If the patient were a girl of that age I should lean in the direction of a congenital anomaly

Figure 1. *Photomicrograph of the Pheochromocytoma of the Adrenal Medulla. Note the compressed cortex on the left.*

condition does occur during the course of severe fulminating hypertension. Was the operation undertaken to relieve sulfadiazine kidneys? Was it on the other hand an operation to relieve the hypertension, which had been planned during the first week of the patient's stay but was delayed because of the sore throat?

Dr. Castleman: The operation was done for the hypertension.

Dr. Derow: The operation was therefore undertaken after the possibilities of sulfadiazine kidneys and glomerulonephritis had been eliminated. The method of dismissing those possibilities is not presented in the record. This patient presented the syndrome of malignant hypertension. He also presented the clinical picture of multiple cerebral thrombosis. He may have had sulfadiazine kidneys or acute glomerulonephritis. He may have had infarction of the right kidney. He may have had an adrenal medullary tumor — a pheochromocytoma.

Dr. J. H. Means: How essential to the diagnosis of adrenal tumor is a definite history of paroxysmal hypertension, which he did not have?

Dr. Derow: I do not know. Most of the cases do give a history of acute paroxysms, with the blood of one or both kidneys, but the fact that this patient was a boy of eighteen does not help in differentiating the possibilities I mentioned.

Clinical Diagnosis

Essential hypertension.

Dr. Derow's Diagnoses

Syndrome of malignant hypertension.
Multiple cerebral thromboses.
Sulfadiazine kidneys?
Glomerulonephritis, acute?
Infarction of right kidney?
Tumor of adrenal medulla (pheochromocytoma)?

Anatomical Diagnosis

Pheochromocytoma of right adrenal gland.

Pathological Discussion

Dr. Castleman: A right lumbodorsal sympathectomy was performed by Dr. Smithwick. During the course of the operation he found a tumor of the right adrenal gland. It was a well-circumscribed tumor measuring 3 cm. in diameter, which he was able to

enucleate from the adrenal gland. A renal biopsy was also performed.

Microscopically the tumor is a pheochromocytoma, — a tumor of the medulla, — but it is of an unusual type. The cells are arranged in a pattern somewhat reminiscent of a neuroblastoma (Fig. 1). I suppose it is possible to have a tumor containing both these types of cells, since originally they arose from the same sympathetic primitive cell or sympathogonia.

DR. DEROW: Did you find acute hemorrhage in the tumor to explain the development of the symptoms that the patient had?

DR. CASTLEMAN: No; just foci of necrosis that you may find in any actively growing tumor.

DR. R. H. SMITHWICK: What did the renal biopsy show?

DR. CASTLEMAN: A perfectly normal kidney, with no evidence of arteriolar disease.

This patient has been well and free from hypertension since his operation two years ago, and a sympathectomy was not necessary on the other side. The cause of his hypertension, therefore, although it was not of the paroxysmal type, was the adrenal tumor.

DR. REGINALD H. SMITHWICK: This case is one of the few with pheochromocytoma without paroxysmal hypertension. I think it is well to stress the fact that this is an extremely rare condition. The great majority of reported cases with pheochromocytoma have had definite paroxysmal hypertension. So far as I know there are only one or two cases in the literature that in any way compare with this one; hence, it is difficult to make a diagnosis of pheochromocytoma in the absence of paroxysmal hypertension.

REFERENCES

1. Derow, H. A., and Altschule, M. D. Malignant hypertension. *New Eng. J. Med.* 213:951-960, 1935.
2. *Idem.* Nature of malignant hypertension. *Ann. Int. Med.* 14:1768-1780, 1941.
3. Derow, H. A. Diagnostic value of serial measurements of albuminuria in ambulatory patients. *New Eng. J. Med.* 227:827-829, 1942.

CASE 30052

PRESENTATION OF CASE

First admission. A sixteen-year-old schoolgirl was admitted because of high blood pressure.

The patient had pseudoarthrosis of the left leg at the age of three, and several operations were performed in various community hospitals. She had diphtheria, measles, chickenpox, whooping cough, tonsillitis and pneumonia as a child, but no history of kidney disease was known. Five months before entry she had an attack of dizziness, headache and unconsciousness, resulting in "complete left hemiplegia." Prior to that time the determination of her blood pressure was of questionable veracity, but one determination eighteen months previously was reported as "112." She was admitted to a community hospital, where the blood pressure was found to be 180 systolic, 120 diastolic. There was a complete left hemiplegia, with slowing of the speech. The spinal fluid was grossly bloody. During the course of the next three weeks the fluid gradually cleared, and the patient began to have some return of function in the arm and leg. The blood-pressure readings varied between 240 systolic, 180 diastolic, and 180 systolic, 110 diastolic. She was found to have a urinary-tract infection and was put on "adequate dosage of sulfadiazine." A urine-concentration test performed at that time showed a fixed specific gravity of about 1.010. A phenolsulfonephthalein test showed 70 per cent excretion in two hours, with 20 per cent in the first twenty minutes. An insulin tolerance test was normal. The paralysis of the face and slurring of the speech disappeared, and there was some improvement in the left leg and arm. She was then transferred to this hospital.

Physical examination showed a well-nourished girl with many brown nevi scattered over the entire body. There was a dorsal scoliosis. The left leg was 7.5 cm. shorter than the right. Excessive hair was present over the arms, legs and abdomen. The heart and lungs were normal. There was deep tenderness in the left flank, and a feeling of fullness, but no masses. Neurologic examination showed papilledema, old and new retinal hemorrhages and albuminuric spots. She was unable to count fingers with either eye. There was a left hemiparesis, and spasticity of the left leg with hyperactive reflexes. The Hoffmann, Oppenheim, Chaddock and Babinski signs were positive on the left.

The blood pressure was 160 systolic, 120 diastolic. The temperature was 99°F., the pulse 80, and the respirations 20.

Examination of the blood showed a red-cell count of 4,610,000, with 13.8 gm. of hemoglobin. The white-cell count was 6500, with 68 per cent neutrophils. A blood Hinton test was negative. The urine was cloudy, with a pH of 5.5. The specific gravity was 1.018. Two to 4 white cells per high-power field were seen in the sediment. The stools were negative.

The blood nonprotein nitrogen was 20 mg. per 100 cc.. the blood sugar 88 mg., and the cholesterol 186 mg. A urine-concentration test showed that the specific gravity was 1.022–1.028. There was no albumin. A phenolsulfonephthalein test was normal. The 17-ketosteroids were 8.4 mg. per 100 cc. in twenty-four hours. The test for follicle-stimulating hormone was positive for at least 6.5 mouse units per twenty-four hours. An electrocardiogram showed a normal rate of 80. The PR interval was 0.14 second. ST_1 was slightly depressed. In Lead 3, the ST segment was slightly elevated and the P and T waves were low.

An x-ray film of the chest showed a slightly enlarged heart. The left ventricle was more rounded than usual. The aorta was slightly tortuous but not dilated. The lungs were clear. An intravenous

pyelogram was negative. Numerous blood-pressure determinations gave averages of 188 systolic, 140 diastolic, while lying down, of 180 systolic, 145 diastolic, while sitting and of 192 systolic, 152 diastolic, while standing. A cold pressor test gave a blood pressure of 220 systolic, 170 diastolic.

She remained essentially the same, and on the twenty-second day a right lumbodorsal sympathectomy was performed. Postoperatively there was no striking change in the blood pressure. On the thirty-seventh day a left lumbodorsal sympathectomy was performed. The blood pressure was not affected, and she was asymptomatic until the sixth postoperative day, when she had a generalized convulsion lasting about five minutes, with associated urinary incontinence and biting of the lips. During the attack the head was turned to the right and there was considerable frothing at the mouth. Following the attack the blood pressure was 260 systolic, 170 diastolic.

Six days later she had "a second brief seizure." Four days later a lumbar puncture gave an initial pressure of 180 mm. of water, and 3 cc. of clear fluid was withdrawn. The total protein was 213 mg. per 100 cc., and there were no cells. The vomiting and headache persisted. The patient complained of inability to see. Examination of the fundi showed 4 to 5 diopters of choking of the right disk, and 3 of the left. X-ray examination of the skull was negative. A second lumbar puncture, eight days after the previous one and performed at the height of a headache, showed an initial pressure of 310 mm.; 10 cc. of clear colorless fluid was withdrawn. A subtemporal decompression was performed. The blood pressure was 240 systolic, 190 diastolic. The blood nonprotein nitrogen was 18 mg. per 100 cc. The patient eventually improved and was discharged on the eighty-sixth hospital day.

Final admission (five days later). The patient remained well until two days before admission, when she had seven convulsive seizures and became unresponsive.

Examination showed an emaciated, stuporous girl with a left hemiplegia and a positive Babinski on the right. The decompression site was bulging. The blood pressure was 255 systolic, 175 diastolic, the temperature 102°F., the pulse 120, and the respirations 20.

The urine was acid, with a specific gravity of 1.020 and positive tests for diacetic acid and acetone; the sediment contained 1 to 5 white cells and 1 to 5 red cells per high-power field. The nonprotein nitrogen was 45 mg. per 100 cc., the carbon dioxide combining power 23.3 millimols per liter, and the chloride 100.5 milliequiv. per liter.

The patient failed to regain consciousness and died on the fourth hospital day.

Differential Diagnosis

Dr. Paul D. White: The pseudoarthrosis, I suppose, represents an ununited fracture.

Apparently there was a sudden fulminating onset to this illness.

The blood pressure was consistent with malignant hypertension.

"She was found to have a urinary-tract infection and was put on 'adequate dosage of sulfadiazine.'" Previously, she had had no history of kidney infection, and I wonder if this was not secondary to her serious prolonged illness rather than an important primary factor.

The relation between the hemiplegia due to the cerebral lesion, whatever it may have been, and the blood pressure is of prime interest. I wonder which was cart and which was horse.

The hirsutism impressed me, and I looked for further manifestations along this line to indicate something like Cushing's disease, but that was all I found. It may suggest adrenal hyperplasia.

The abdominal examination leaves me uncertain whether or not a tumor was present in the left flank.

The severe retinopathy might certainly have been hypertensive.

The difficulty with sight was much more marked than that usually seen in hypertensive retinopathy and suggests optic atrophy.

I was not sure what the Hoffmann sign was, and so I looked it up. It is flexion of the terminal phalanx of the thumb and of the second and third phalanges of the fingers when the nails are suddenly pressed. The Oppenheim is extension of the toes when the inner side of the leg is scratched or stroked. The Chaddock is positive when, on irritating the external malleolar skin area, the great toe extends, as in cases of organic disease of the corticospinal reflex paths; it resembles the Babinski.

The laboratory findings were essentially negative. Dr. Albright told me this morning that a value of 8.4 mg. for the 17-ketosteroids is a normal finding. The electrocardiogram was normal. It looks as if aortic disease was not present, but that there might have been a little hypertensive heart disease, with increase in the size of the left ventricle.

After the first operation "there was no striking change in the blood pressure." One does not expect a drop that early even if the result is eventually successful. The blood pressure should have been affected by the second operation, however, if the procedure was going to be beneficial. All the cases that I have seen that were successful had an early drop in blood pressure after the second operation.

The episode on the sixth postoperative day sounds like an epileptic fit.

There apparently was no deformity of the sella turcica, and the bones were not porous. The subtemporal decompression was evidently done to relieve pressure.

We have three chief problems: first, the cause of the hypertension; second, the relation of the hypertension to the cerebral lesion; and third, the cause of death. I do not believe that there is any good evi-

dence for renal etiology, for coarctation of the aorta or for subarachnoid hemorrhage, either primary or secondary. Hypertension may be found in cases with subarachnoid hemorrhage, but usually the blood pressure is normal and is not elevated much by such a hemorrhage.

I have read over the features of Cushing's syndrome, — that is, basophilic adenoma of the pituitary, — and this case does not seem to fit. The girl was not painfully obese, nor did she have striking sex changes. Also, the hypertension seems much too great. I do not recall having cases with such a high pressure brought to my attention. The adrenocortical syndrome does not fit either, that is, with tumors in the usual sites, unless Dr. Smithwick, who did this operation, removed one that we may hear about later and unless something else came from it. I know that Dr. Smithwick in his lumbodorsal splanchnic resections explores the kidneys and the ordinary sites of adrenal tumors. Could there have been a simple cortical adrenal hyperplasia, unidentifiable by gross inspection, that produced the situation found in this patient?

A rare ovarian tumor, known as arrhenoblastoma, has been noted to cause hypertension and excessive hair, without hyperglycemia or osteoporosis. But there is no evidence of that here. There was a suggestion of something in the left flank, but I cannot diagnose such a tumor on that basis.

Essential hypertension is possible even at an early age, but it must be considered as extremely rare under twenty. Some, probably considerable, evidence against such a diagnosis is the failure of bilateral lumbodorsal splanchnic resection to budge the blood pressure. In every young person with essential hypertension that I have known who has been operated on by Dr. Smithwick there has been a distinct change in the blood pressure after bilateral lumbodorsal sympathectomy. I should like a comment on that from Dr. Smithwick himself.

Finally, one must consider a brain tumor that involved, by pressure, the temporal area and motor cortex on the right and the optic nerves, with initial hemorrhage into the ventricles and spinal canal and resulting secondarily in generalized hypertension.

Dr. John Abbott: May I contribute one item that is not recorded in the history? An electroencephalogram indicated a lesion of the motor cortex, maximal in the right temporal region.

Dr. White: I thought from the data I had that brain tumor might be the best bet, but it is extremely rare in my experience to be asked to see anyone with hypertension of which brain tumor is the cause. Of course cerebral hemorrhage can be induced by either hypertension or brain tumor. I should like to ask the neurologic experts how much vascular hypertension can be produced by a brain tumor. I think that it is much less likely to discover in such a young person what we might find in a middle-aged or older person — namely, cerebral vascular disease with apoplexy secondary to essential hypertension.

If it was a tumor, I do not know the type. Perhaps it was a glioma. A metastatic tumor in the brain has to be considered. I was rather intrigued by the thought that it might have been a hypernephroma; but that is very, very rare.

Clinical Diagnosis

Hypertension.

Dr. White's Diagnosis

Hypertension and cerebral hemorrhage of unknown cause, perhaps due to brain tumor.

Anatomical Diagnoses

Occlusion of orifices of renal arteries: complete (right) and partial (left).

Arteriosclerosis: left kidney, spleen, pancreas and brain.

Cardiac hypertrophy, hypertensive type.

Cerebral infarction, with secondary hemorrhage: right lenticular nucleus.

Bronchopneumonia, terminal.

Pathological Discussion

Dr. Benjamin Castleman: The striking finding was in the orifices of the renal arteries in the aorta. In place of the orifice of the right renal artery we were able to find only a dimpling of the intima; the proximal 6 mm. of the vessel was narrowed by fibrous tissue to a mere pinpoint, if open at all (Fig. 1). Then the vessel abruptly became patent, with a circumference of about 10 mm., the point of dilatation being where the suprarenal branch was given off. The orifice of the left renal artery, although not occluded by fibrous tissue like the right, was markedly constricted to about 1 mm. in diameter for a distance of about 3 mm.; it then dilated to about 15 mm. in circumference. Distal to the occlusion on the right and within the narrowed portion on the left were small, fairly recent thrombi. We have, therefore, a situation in man analogous to the Goldblatt dog, in which hypertension is produced by clamping both renal arteries. I am at a loss to explain the pathogenesis of this process. Microscopic examination of sections through the points of occlusion and narrowing show merely old organized fibrous tissue, which may at one time have been thrombi superimposed on an arteriosclerotic lesion.

Another interesting finding was the presence of a moderate degree of arteriolarsclerosis in the left kidney and none in the right. This is also somewhat analogous to the rare form of hypertension due to a unilateral ischemic kidney, in which arteriolar changes are found only in the opposite kidney.

The heart was enlarged, weighing 300 gm.

The changes in the brain were those of an infarct with secondary hemorrhage, at least that is what Dr. Kubik believes it to be rather than the result of cerebral hemorrhage. There was severe diffuse vascular disease in the small vessels of the brain.

DR. REGINALD H. SMITHWICK: We now have several hundred cases of hypertension treated surgically, and Dr. Castleman has dipped into this group and selected two of the rarest for discussion today. The second case is the only example of this sort in the series, and I have never come across such a case in the literature.

DR. WHITE: Did you find this at operation?

DR. SMITHWICK: No, because the occlusions were practically within the aorta. The operative field permits careful examination of most of the renal artery, the kidney and the adrenal gland; the extra-aortic part of the renal artery, however, did not impress me as being particularly remarkable. Incidentally, it is extremely important, in any operation for hypertension, to include exploration of the kidneys and adrenal glands. As you can see, this case here is about as close a counterpart of the Goldblatt syndrome in dogs as one could possibly see in a human being, and as I have said, is the only case in our experience. The only thing that was missing was the actual presence of the clamp itself.

DR. WHITE: What did you think after the operation failed to bring down the pressure? You knew that something was wrong?

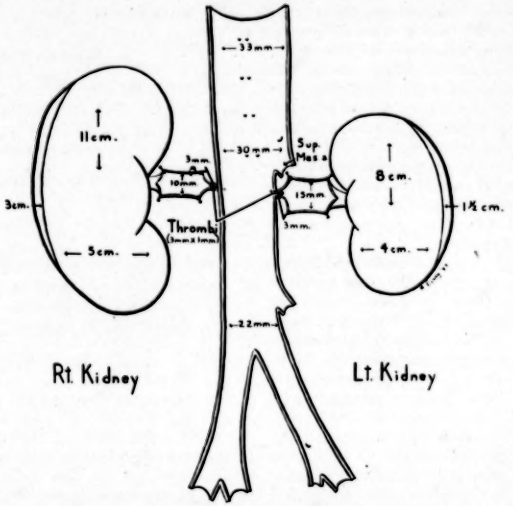

FIGURE 1. *Schematic Drawing of Arterial Supply of Kidneys Showing Occlusion of the Orifices of the Renal Arteries.*

DR. SMITHWICK: Yes, because that was not what I anticipated.

DR. WHITE: What percentage do you bring down at that age?

DR. SMITHWICK: Between 80 and 90 per cent.

DR. WHITE: Dr. Ayer, how often do you see hypertension with brain tumor?

DR. JAMES B. AYER: We rarely see as much hypertension as this patient showed.

DR. WHITE: The association of hypertension and brain tumor is commonly referred to in textbooks, but I wonder how often you actually encounter it.

DR. AYER: Practically never.

The New England
Journal of Medicine

Formerly
The Boston Medical and Surgical Journal
Established 1828

Owned by the Massachusetts Medical Society and Published under the Jurisdiction of the Committee on Publications

Richard M. Smith, M.D., *Chairman*
James P. O'Hare, M.D. William B. Breed, M.D.
Conrad Wesselhoeft, M.D. Oliver Cope, M.D.

Official Organ of
The Massachusetts Medical Society
and
The New Hampshire Medical Society

Editorial Board
Joseph Garland, M.D. A. Warren Stearns, M.D.
Shields Warren, M.D. Dwight O'Hara, M.D.
C. Guy Lane, M.D. Chester S. Keefer, M.D.
William A. Rogers, M.D. Howard M. Clute, M.D.
Stephen Rushmore, M.D. Fletcher H. Colby, M.D.
Henry R. Viets, M.D. Robert L. Goodale, M.D.
Robert M. Green, M.D. Chester M. Jones, M.D.
Charles C. Lund, M.D. Harvey R. Morrison, M.D.

Associate Editors
Thomas H. Lanman, M.D. Donald Munro, M.D.
Henry Jackson, Jr., M.D.
Walter P. Bowers, M.D., Editor Emeritus
Robert N. Nye, M.D., Managing Editor
Clara D. Davies, Assistant Editor

Subscription Terms: $6.00 per year in advance, postage paid, for the United States (medical students, $3.50 per year); Canada, $7.04 per year (Boston funds); $8.52 per year for all foreign countries belonging to the Postal Union.

Material for early publication should be received not later than noon on Friday.

The Journal does not hold itself responsible for statements made by any contributor.

Communications should be addressed to the *New England Journal of Medicine*, 8 Fenway, Boston 15, Massachusetts.

PATULIN AND THE COMMON COLD

"What's good for a cold?" This question has always been certain to embarrass physicians since they, too, would be glad to have the answer to that question and employ it whenever they were troubled by this common malady. When a remedy for the common cold is offered, and particularly if that remedy happens to be in the form of an agent related to such a widely hailed and effective substance as penicillin, it is easy to understand why physicians and the lay public are both interested and intrigued. Such a remedy is discussed in a recent issue of the *Lancet*,* which contains a report on the use of patulin in the common cold. This study is the result of a collaborative research by a group of biochemists in the London School of Tropical Medicine and Hygiene and by a number of clinical investigators.

Patulin is the name given to a substance obtained as a metabolic product from the filtrate of cultures of *Penicillium patulum*. This new agent is of great interest for several reasons. The active substance has been isolated and crystallized, and its chemical structure has been defined. It happens to be a relatively simple chemical compound. The yields of this material from cultures are relatively large as compared with those of similar products, such as penicillin. Furthermore, it seems to be equally effective against both gram-positive and gram-negative bacteria. Against the gram-positive organisms it is less effective than penicillin, whereas against the gram-negative ones it is more effective. The substance is quite stable in the crystalline form, but some changes do take place if an aqueous solution is permitted to stand at room temperature for several days. It is not inactivated by either serum or pus.

On the other hand, the results of toxicity experiments indicate that this drug has a much narrower range of safety between concentrations that are effective and those that are toxic. In acute toxicity experiments the average lethal dose was 0.5 mg. for a 20-gm. mouse. This amount given either intravenously or subcutaneously produced death accompanied by widespread capillary damage in the liver, spleen and kidneys as well as pulmonary hemorrhages and edema. Convulsions occurred soon after the material was given intravenously. Similar toxicity was observed in rabbits with even smaller amounts. When injected subcutaneously in animals, it produced local necrosis. The substance was also toxic to leukocytes. It was found that phagocytosis of killed staphylococci by leukocytes was unaffected by a dilution of 1:8000 but was completely inhibited when a dilution of 1:2000 was used.

The reported clinical trials concern only its use in the common cold, which is usually considered to be a virus disease. Cases having a protracted course are usually those in which the virus infection is followed by a bacterial complication of the nose,

*Raistrick, H., and others. Patulin in common cold. Collaborative research on derivative of *Penicillium patulum* Bainier. *Lancet* 2:625-635, 1943.

pharynx or accessory nasal sinuses. Such complications are the result of infection with the common respiratory pathogens, and these appear to be amenable to the use of patulin. The method used in the clinical trials consisted of either spraying the nose and throat, douching the nose, or sniffing. It was used in a buffered aqueous solution and administered every four hours in dilutions of 1:5000 to 1:20,000. The more concentrated solution produced local irritation, some patients complaining of transitory stinging and others of a profuse nasal discharge for about half an hour. This was not noted with the more dilute solutions. Apparently no other ill effects were observed.

Interestingly enough, the first clinical trial was by Dr. W. E. Gye, director of the Imperial Cancer Research Fund Laboratory, who was given a supply of the material for an experimental study of its effect in cancer. Dr. Gye was suffering from a severe cold at the time that he received the substance so he made up a solution, sniffed it and was rapidly relieved of his symptoms. He then supplied some of the material to colleagues, who likewise felt that the chief symptoms of their colds were rapidly alleviated. Dr. Gye's note makes no mention of the effect of this substance in experimental cancer.

The material was then supplied to Surgeon Commander Hopkins, of the Royal Navy, who reported on the antibacterial efficacy of the drug as well as on its toxicity in animals. He also set up two types of clinical study: a control series among officers and enlisted men who volunteered for treatment and an evaluation of the clinical effects based on careful notes by colleagues and friends. The cases were carefully selected to exclude persons who already had evidence of complicating infections and also to eliminate cases of clinical influenza. The results of the control study showed that 58 per cent of 95 persons receiving patulin in various concentrations during the first few days of an uncomplicated cold were "cured" within forty-eight hours. In 85 control patients who received a solution of the buffer without patulin less than 10 per cent were benefited within this same period. The data were reviewed by Major Greenwood, a professor of epidemiology and vital statistics, and were found to be statistically significant. They calculated that the probability of these results being a matter of chance was only three in ten thousand. A smaller number of cases diagnosed clinically as influenza were treated without beneficial effects. Interestingly enough, in those patients treated for the common cold who previously had had frequent colds that were followed by sinusitis, only temporary improvement was noted and sinusitis was not prevented when patulin was used, presumably because the drug did not reach the infected areas.

Most of the physicians who were asked to use the material personally and to make careful notes of the results were quite enthusiastic. They stated that their symptoms were rapidly alleviated. On the other hand, this group also contained a number in whom symptoms of sinusitis were not prevented. In many of the subjects who responded favorably, the acute symptoms often completely disappeared within a few hours; many, however, had a recurrence of discharge from and stuffiness of the nasal passages after a few hours and this was repeated several times before they were completely relieved. No ill effects were noted beyond the local irritation when the larger doses were used.

In view of the fact that the most serious types of complication of the common cold were not prevented, further elucidation of the mechanism whereby the results were obtained seems necessary. Although extensive clinical trials are indicated, there is little prospect of any large supply being immediately available. Furthermore, a great deal more should be known about the pharmacologic actions of the drug in human cases as well as in animals before any widespread use is permitted.

The fact that the chemical formula of the substance is known opens a wide field for further study. First of all, one may anticipate that it will be possible to synthesize this material. When sufficient materials are thus made available, one may anticipate numerous modifications of the chemical structure in the hope of reducing its toxicity and increasing its effectiveness, as has been true of the sulfonamides. In addition, the findings seem to justify extensive research on antibacterial substances from molds and other higher bacteria. One may expect much progress in this field in the next few years.

HOLMES AS A PSYCHIATRIST

The medical aspects of Holmes's career are being re-examined and re-evaluated. His place in American literature is secure, but many are asking what about his niche in American medicine? Did he, except for his outstanding contribution in 1843 to preventive medicine, the paper "On the Contagiousness of Puerperal Fever," exert any considerable influence on the trend of medical thought or leave buried in his writings material not fully appreciated at the time of its writing, or since? Undoubtedly the stamp of Holmes's dynamic character left an impression on a generation or more of the medical students who attended his anatomical lectures. He gave an impetus, moreover, to the public demonstration of the administration of ether by coining the term "anesthesia," stimulated research with the aid of the microscope and used his vast influence in 1875 to re-establish the Boston Medical Library for his generation and for posterity. These are, however, as time has listed them, minor contributions. What else did Holmes add to the medical scene? What about the "medicated novels," and Holmes as a psychiatrist?

Little attention has been paid to Holmes's interests in mental aberration or to Holmes as a clinical psychiatrist. It is now realized, thanks to the researches of Oberndorf,* that Holmes was long a profound student of mental disease and that he had pronounced and advanced ideas on mental mechanisms. Possibly hesitant about presenting his thoughts before his medical colleagues, or at least doubtful about their acceptance in the form of a medical paper, he chose the medium of the novel to bring his opinions before the public. Neither *Elsie Venner* (1859) nor *The Guardian Angel* (1867) was a literary product of excellent quality when compared with contemporary works of Poe, Thackeray and Hawthorne. But they were studies of the abnormal mind, and simple though the stories are, both books give us an insight into Holmes's profound psychiatric understanding. His doctors, moreover, combine, as noted by Oberndorf, "those qualities so desirable in every physician but indispensable in a psychiatrist — namely, patience, forbearance, tolerance, equanimity, accurate observation of the patient's actions and utterances, and unremitting consideration for the patient's psychological and environmental handicaps."

Following the novels, Holmes became so engrossed in the theme of the social significance of mental deviation that he chose this subject for his address to the Phi Beta Kappa Society at Harvard in 1871. "Mechanism in Thought and Morals," as the paper was called, was withheld from publication for more than twenty years, and only after careful revision, expansion and annotation had taken place, did Holmes allow it to appear in print, hidden in *Pages from an Old Volume of Life* (1892). There, this address, with its modern flavor and psychoanalytical leanings, has been allowed to rest nearly unnoticed. In this essay will be found opinions strangely similar to those so reluctantly accepted by the medical profession after they were re-emphasized by Freud forty years later. In the brain, Holmes considered, there persists a material record of thought; and secondly, this transmissible record is not at all times available to the person for the control of his actions. Are these ideas not the "indestructibility of infantile thought and impressions" and the "importance and influence of unconscious mentation" — the foundation stones of Freud's psychoanalytic structure? At least Oberndorf thinks so, and his book makes a strong case in Holmes's favor. Except for a pleasant whimsicality, so characteristic of Holmes, the following passage from his address might well have been written by Freud in 1910:

> There are thoughts that never emerge into consciousness, which yet make their influence felt among the perceptible mental currents, just as the unseen planets sway the movements of those which are watched and mapped by the astronomer. Old prejudices, that are ashamed to confess themselves, nudge our talking thought to utter their magisterial veto. In hours of languor, as Mr. Lecky has remarked, the beliefs and fancies of obsolete conditions are apt to take advantage of us. We know very little of the contents of our minds until some sudden jar brings out the old stockings full of gold, and all the hoards that have hid away in holes and crannies.

*Oberndorf, C. P. *The Psychiatric Novels of Oliver Wendell Holmes* New York: Columbia University Press, 1943.

MEDICAL EPONYM

Scheuermann's Disease

Dr. Holger Werfel Scheuermann (b. 1877), of Copenhagen, Denmark, described "Kyfosis dorsalis juvenilis [Juvenile dorsal kyphosis]" in the *Ugeskrift*

for laeger (**82**: 385-393, 1920). A German summary may be found in *Zeitschrift für Orthopädie und ihre Grenzgebiete* (**41**:305, 1921), and an English summary appears in *Acta Chirurgica Scandinavica* (**54**: 29, 1922). A portion of the latter follows:

> Among spinal deviations at the age of puberty there are many cases which clinically and morphologically form a complete group. These are real fixed kyphoses in columna dorsalis or dorsolumbalis in arcuate form. . . .
>
> The cause . . . lies, in my opinion, in the morbid condition of the growing-area between the epiphysis and corpus. . . .

R. W. B.

MASSACHUSETTS MEDICAL SOCIETY

DEATHS

EGAN — John J. Egan, M.D., of Gloucester, died January 22. He was in his seventy-fourth year.

Dr. Egan received his degree from Harvard Medical School in 1894. He was a member of the Massachusetts Medical Society and the American Medical Association.

Three sons and a daughter survive.

LOWENTHAL — Karl Lowenthal, M.D., of Fall River, died January 16. He was in his fifty-second year.

Dr. Lowenthal received his degree from Albert-Ludwigs-Universität Medizinische Fakultät, Freiburg, Baden, in 1915. He was a member of the Massachusetts Medical Society and the American Medical Association.

His widow survives.

STEIN—Albert Stein, M.D., of Thompsonville, Connecticut, died December 5, 1942. He was in his fiftieth year.

Dr. Stein received his degree from the University of Maryland School of Medicine and College of Physicians and Surgeons in 1917. He was a member of the Massachusetts Medical Society and the American Medical Association.

WAR ACTIVITIES

INDUSTRIAL MEDICINE

Allowable Concentrations of Toxic Dusts and Gases

At a recent meeting of the committee of the American Standards Association concerned with approval of allowable concentrations of toxic dusts and gases, it was reported that six standards had been approved during the present calendar year, and that altogether twelve standards had been promulgated under the auspices of the committee since its reorganization two years ago.

The standards now being considered are on methanol, styrene monomer, formaldehyde, trichlorethylene and acrylonitrile. A standard on toluene has been approved and published. The proposed standards for oxides of nitrogen approved by the committee are now being processed through the Safety Code Correlating Committee.

Considerable discussion was given to the preparation of a standard for exposure to silica dust. It was finally decided to prepare a standard that would take into consideration the data now available for threshold limits for various industrial dusts with a silica content. The consensus was that no single maximum allowable concentration could be developed in view of the fact that no two dusts containing silica have the same effect on health, even when the silica content is the same.

The chairman was authorized to appoint subcommittees to consider the following standards: methyl chloride, which is now being used in place of Freon as a refrigerant; hydrofluoric acid, fluorine and fluorides; and radon, gamma rays and radium dust.

It was agreed by the committee that the recently circularized code on carbon tetrachloride should be rewritten, with a footnote to the effect that subjective symptoms may be experienced when workers are exposed to concentrations lower than 100 parts per million and, for that reason, that attempts should be made to achieve concentrations lower than the standard recommended.

MISCELLANY

AMERICAN COLLEGE OF SURGEONS

Twenty-two cities throughout the United States and Canada have been selected by the American College of Surgeons as headquarters for one-day "war sessions" to be held in March and April. Advancements in military medicine and developments in civilian medical research and practice under the spur of the war emergency will be presented by authorities representing governmental agencies and by civilian physicians and surgeons. The meetings will be open to the profession at large, including medical officers of the Army and the Navy, residents, interns, medical students and executive personnel in hospitals. For the last, special hospital conferences, to be held simultaneously with the scientific sessions, are being arranged.

Each meeting will open at 8:30 a.m. with the showing of official Army and Navy films on medical and surgical subjects, such as evacuation of the wounded, fractures, bomb blast, burns and treatment of wounds. From 9:30 to 11:30, Army and Navy representatives who have been on active duty abroad will report; from 11:30 to noon, representatives of the United States Public Health Service will report on measures for the control of endemic and epidemic diseases. Current problems of the Procurement and Assignment Service will be presented by a representative at the luncheon conference from 12:15 to 2:00 o'clock. Between 2:15 and 5:00 scientific presentations by medical members of the armed forces and of the Veterans Administration and by civilian members of the medical profession, including someone engaged in the practice of industrial medicine, will be made. From 5:00 to 5:30 the need for protective service in time of war will be presented by a representative of the Office of Civilian Defense. The concluding session will be a dinner meeting and open forum with all participants in the day's program as the panel of experts to lead discussion of any and all subjects presented during the day, together with other problems of interest to the medical and hospital professions. The motion-picture showing, Public Health Service session, luncheon conference, Civilian Defense program and dinner meeting will be attended by both the medical and hospital groups. The hospital representatives will discuss wartime hospital problems and how they are being solved from 9:30 to 11:30, and will hold a round-table conference on "Wartime Hospital Service" from 2:15 to 5:00.

The preliminary schedule for the meetings is as follows:

Date	City	States and Provinces
February 28	Winnipeg	Manitoba, Saskatchewan
March 2	Minneapolis	Minnesota, North Dakota, South Dakota
March 4	Des Moines	Iowa, Nebraska, Missouri
March 6	Chicago	Illinois, Wisconsin
March 8	Cincinnati	Ohio, Kentucky, Indiana, West Virginia
March 10	Detroit	Michigan
March 13	Rochester	New York State
March 15	Toronto	Ontario
March 17	Montreal	Quebec, New Brunswick, Nova Scotia, Prince Edward Island, Newfoundland
March 20	Springfield	Massachusetts, Maine, New Hampshire, Vermont, Rhode Island, Connecticut
March 22	Philadelphia	Pennsylvania, New Jersey, Delaware
March 24	Baltimore	Maryland, District of Columbia, Virginia
March 27	Jacksonville	Florida, Georgia, North Carolina, Eastern Tennessee
March 29	Jackson	Mississippi, Louisiana, Western Tennessee, Alabama
April 1	San Antonio	Texas, New Mexico, Mexico
April 4	Tulsa	Oklahoma, Kansas, Arkansas
April 7	Denver	Colorado, Wyoming, Western Nebraska
April 11	Salt Lake City	Utah, Idaho
April 14	Spokane	Washington, Northern Idaho, Oregon, Montana
April 18	Vancouver	British Columbia, Alberta
April 24	San Francisco	Northern California, Nevada
April 27	Los Angeles	Southern California, Arizona

(*Books Received on page ix*)